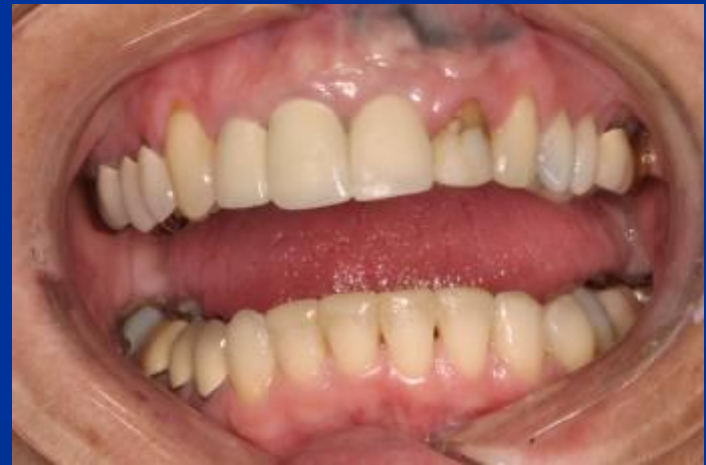

Inland Empire Perio Study Club

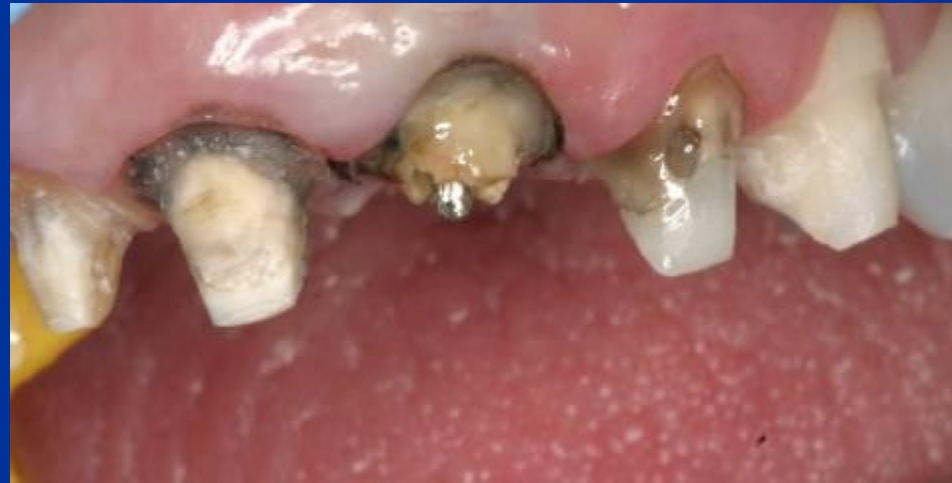Grand Rounds

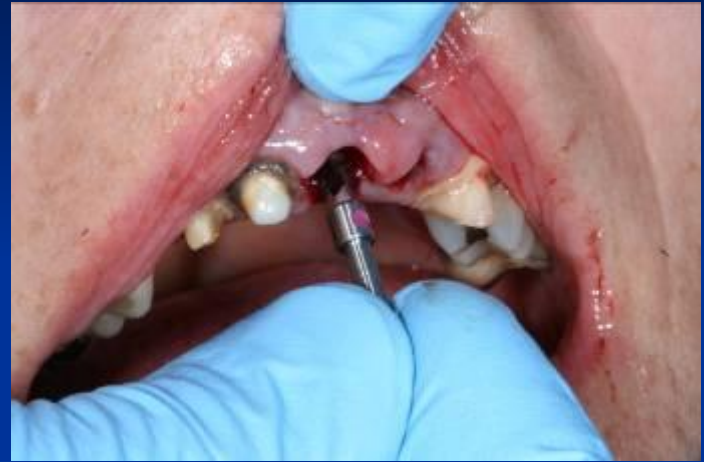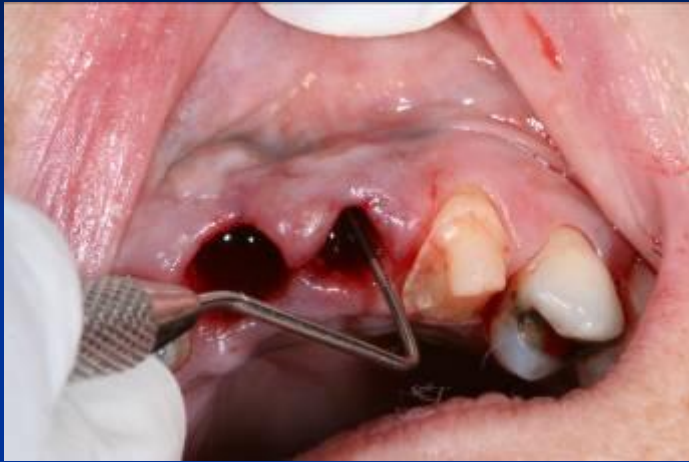Tom Smart

- Preop photos
- Esthetic restorative treatment plan
- Orthodontics and extrusion of #10 which fractured off at gingiva
- History of apical surgery and amalgam retrofills in #9 and #10
- Treatment plan for implant in either #9 or #10 site

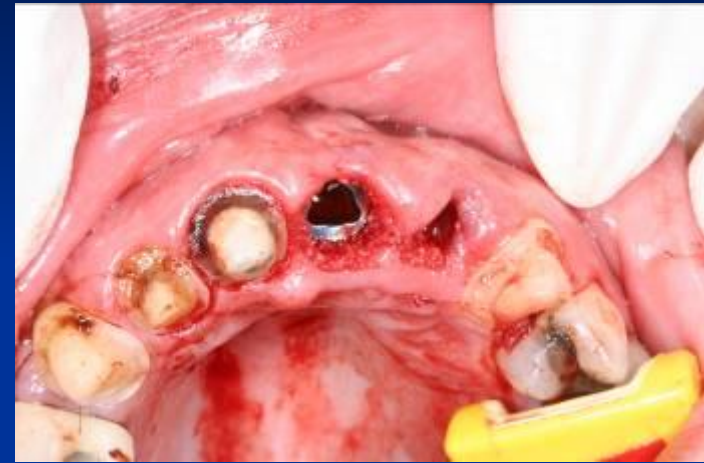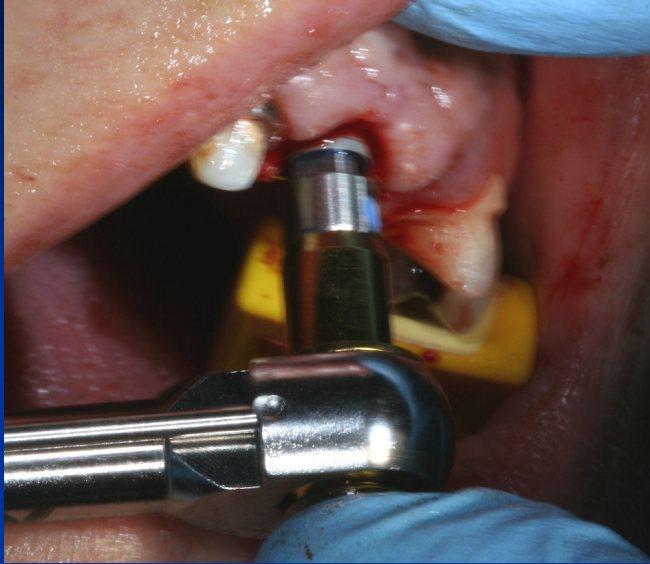


- At the time of the initial preps, #10 appears to be in better condition than #9. Discussion around removing 9, 10 or both.
- Decision to remove both teeth to improve the predictability of the case and plan on placing an implant in the #10 site with the rationale that controlling the esthetics in #9 site as a pontic cantilevered off of #10 would be more favorable than implant in the #9 site

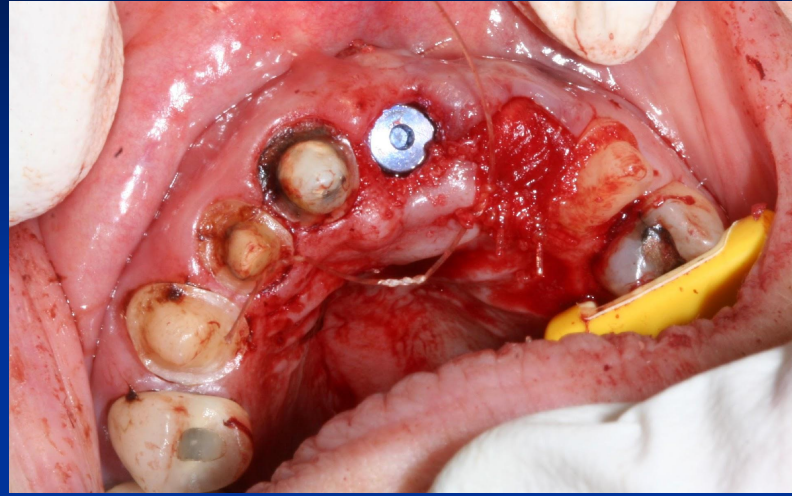
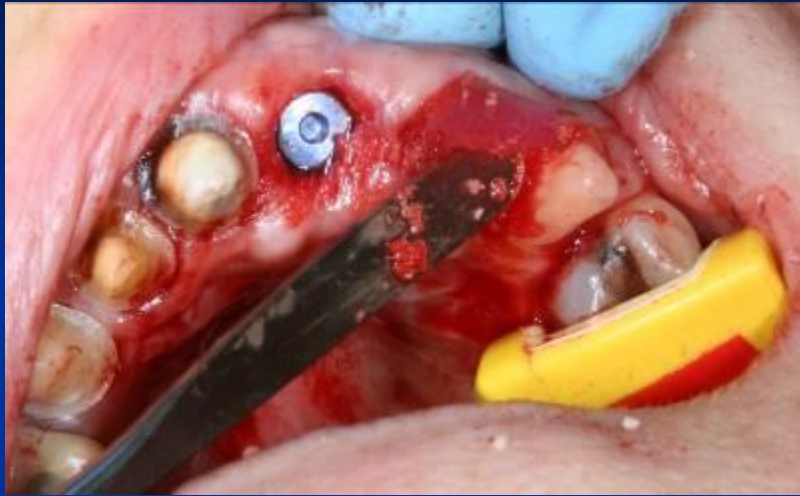



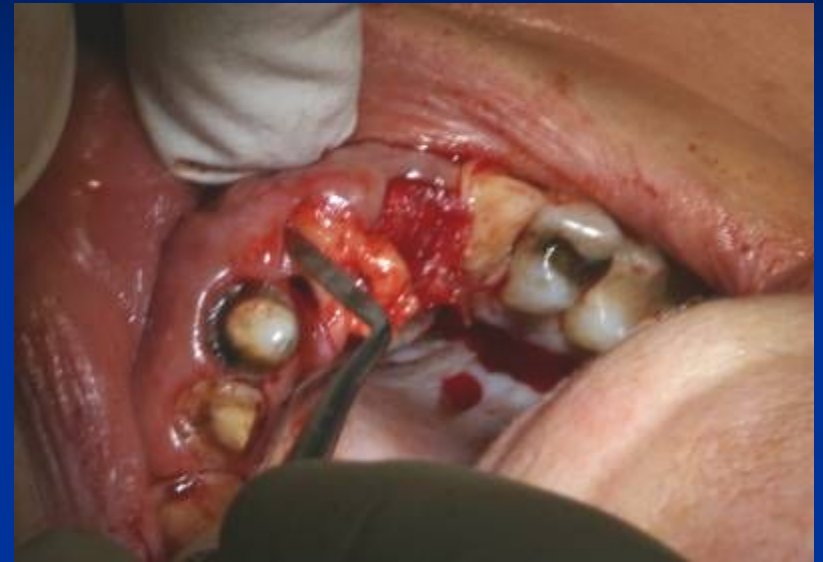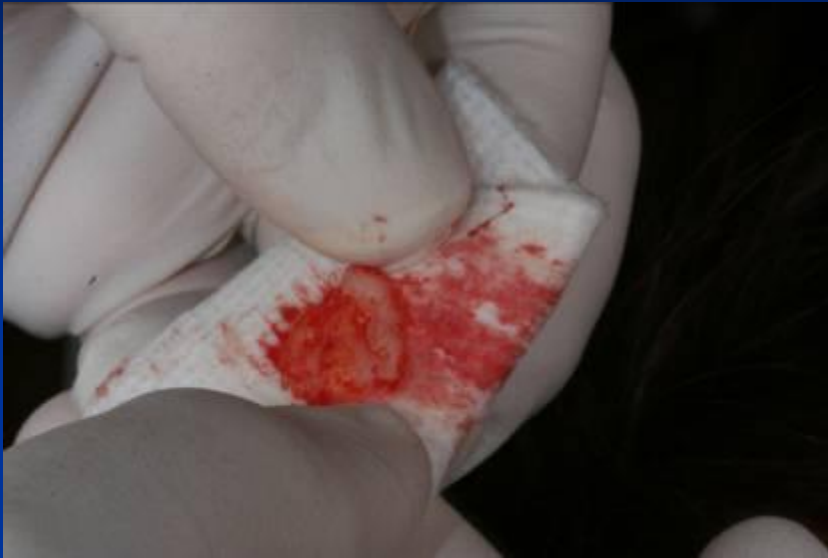- Bone perforated in #10 site
- More buccal bone #9 site, revised treatment plan to place implant in #9 site



- Placement of Nobel Groovy 5.0 x 13mm implant in #9 site
- Placed through bone graft material (Puros cancellous .25-1.0mm)

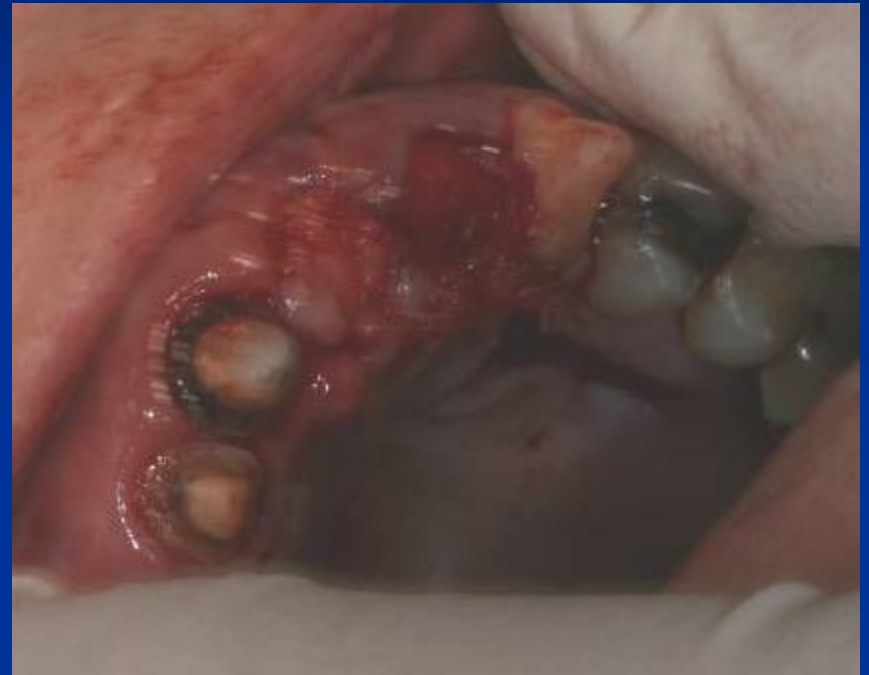

- Use of socket repair membrane (ice cream cone) to repair #10 site

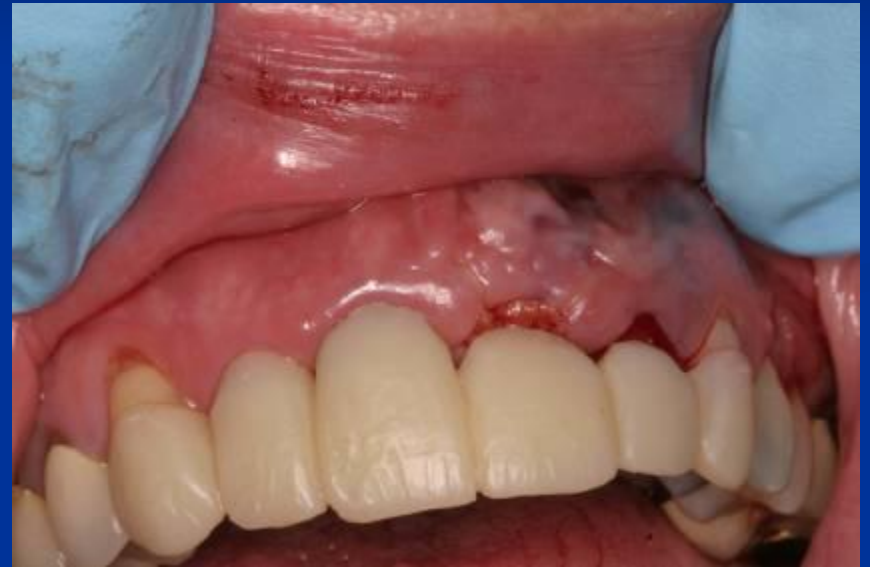

- Placement of connective tissue graft from palate over implant #9 site in order to achieve more fullness to even up the gingival contour between #8 and #9.

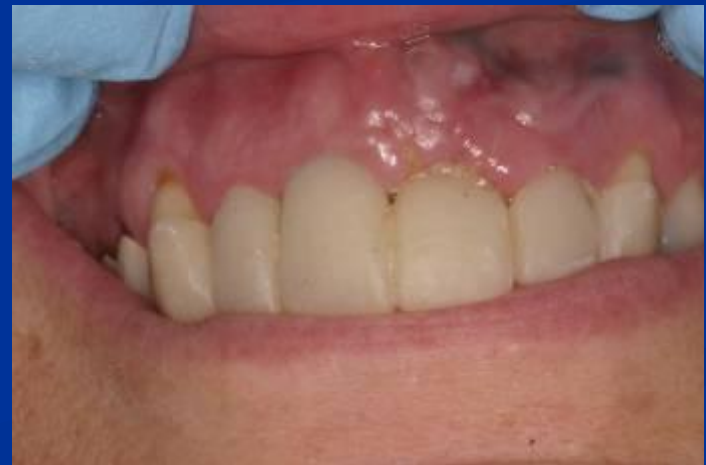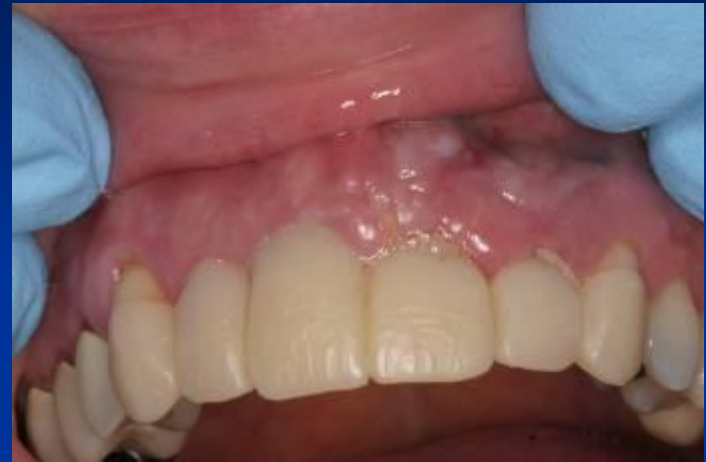- Completed connective tissue graft #9 site
- Completed socket repair #10 site



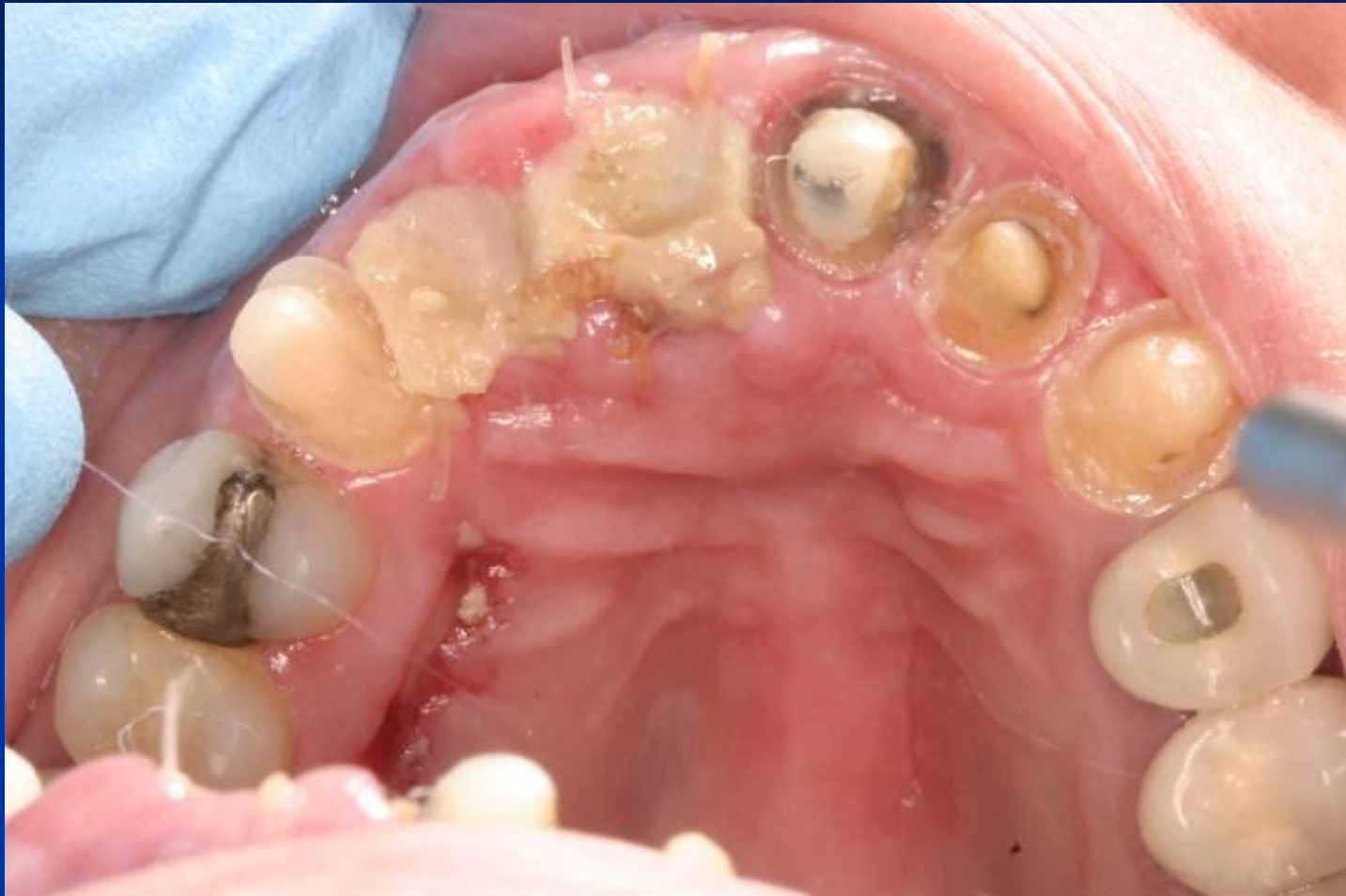- Temp in place day of surgery
- Critique was that #9 pontic was OK contour to stay away from graft, but that #10 should extend to tissue to begin to shape healing.



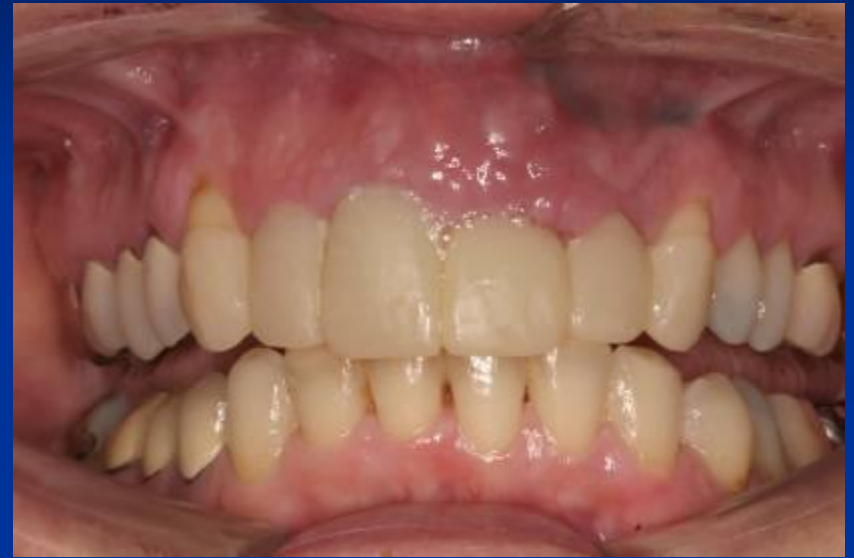- 2 days post op
- Pontic too short on #10
- Added to length of pontic to support tissue



2 days post op

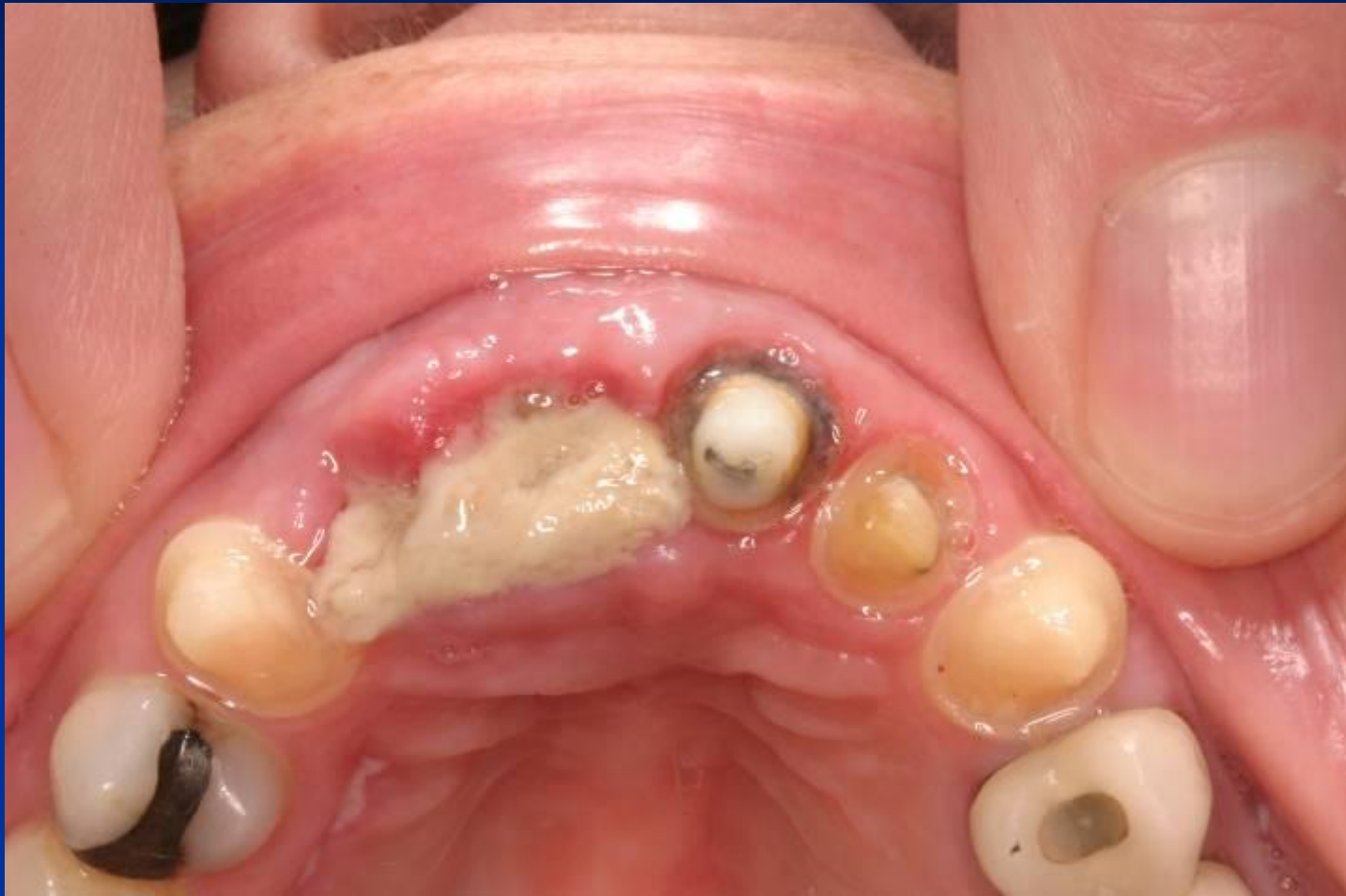

9 days post op

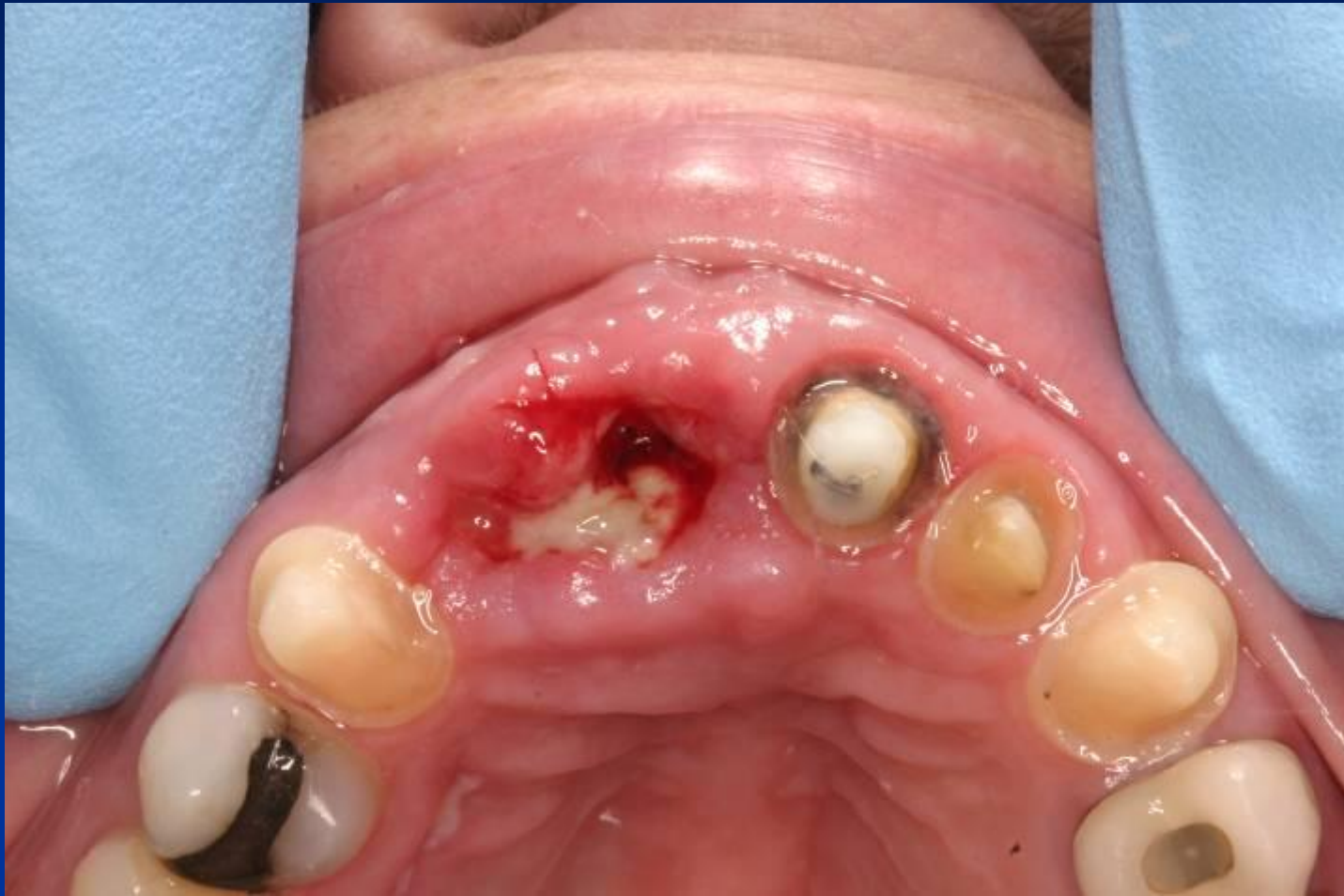

- Pain!!!- narcotics every 4 hours since surgery
- Bad taste and smell, especially in mornings

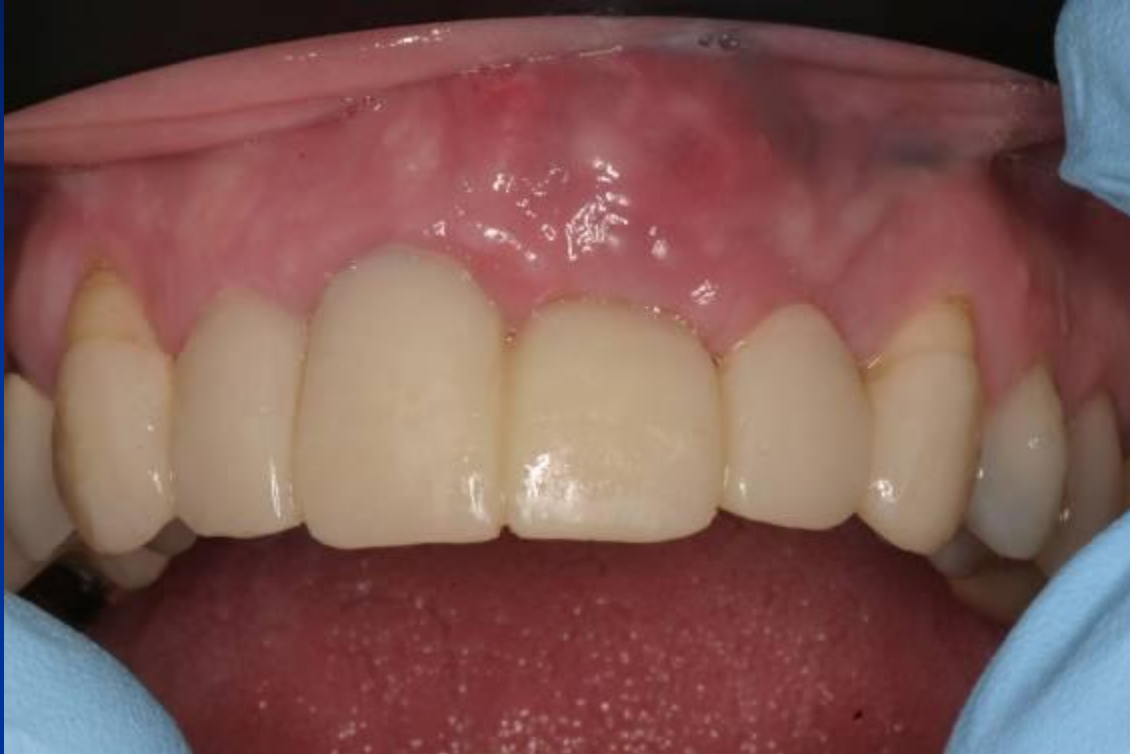– 9 days post op



9 days post op
After trimming necrotic tissue



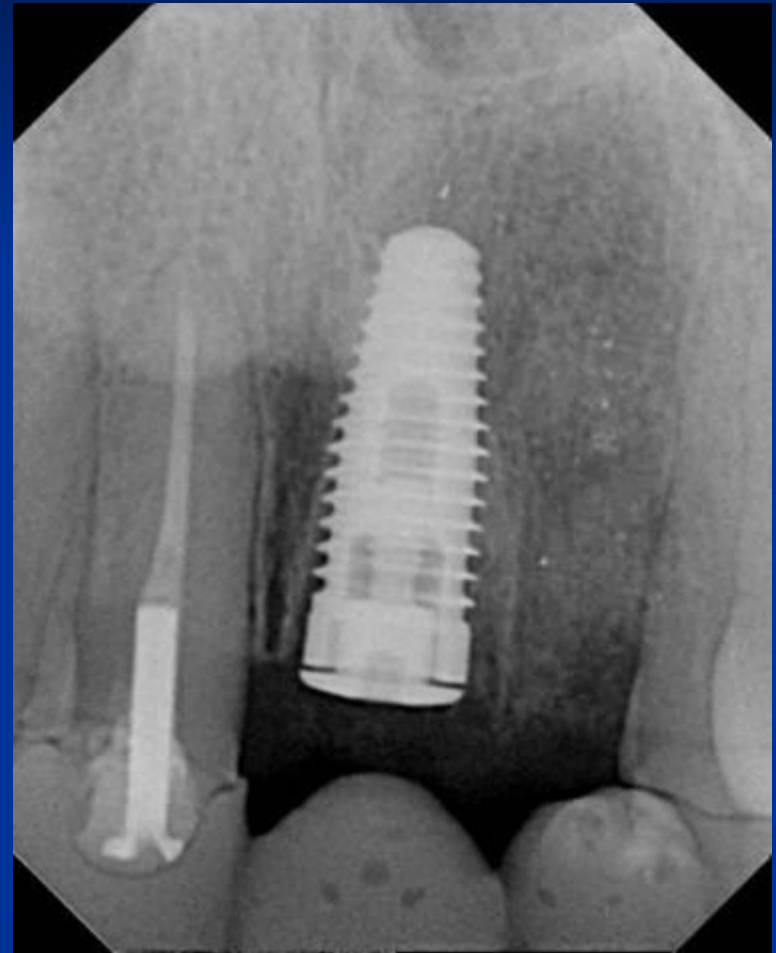
16 days post op



- Continued pain
- Fluctuant swelling facial to #9

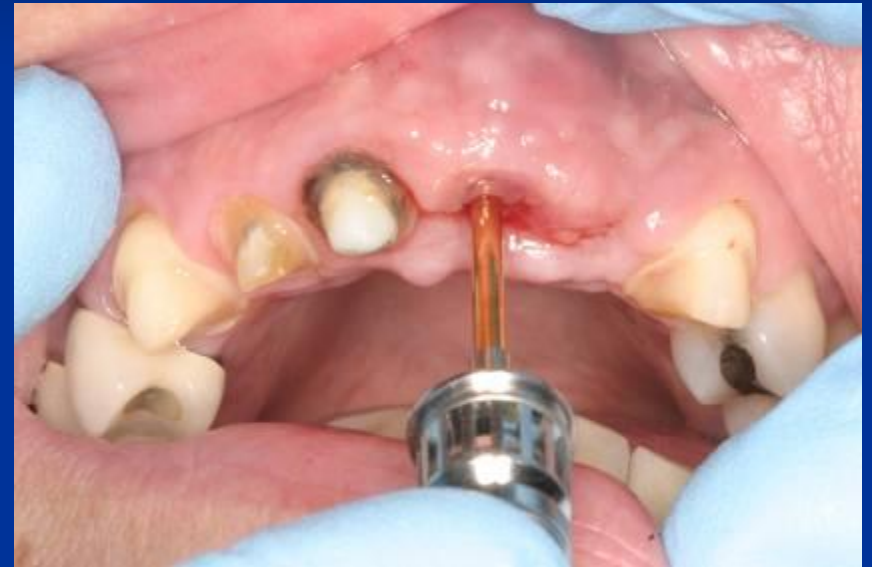16 days post op

- Loose healing cap
- Source of problems?
- Suspect Puros bone graft material on platform of implant when placing healing cap.
- Fatal flaw...no PA before proceeding with connective tissue graft.



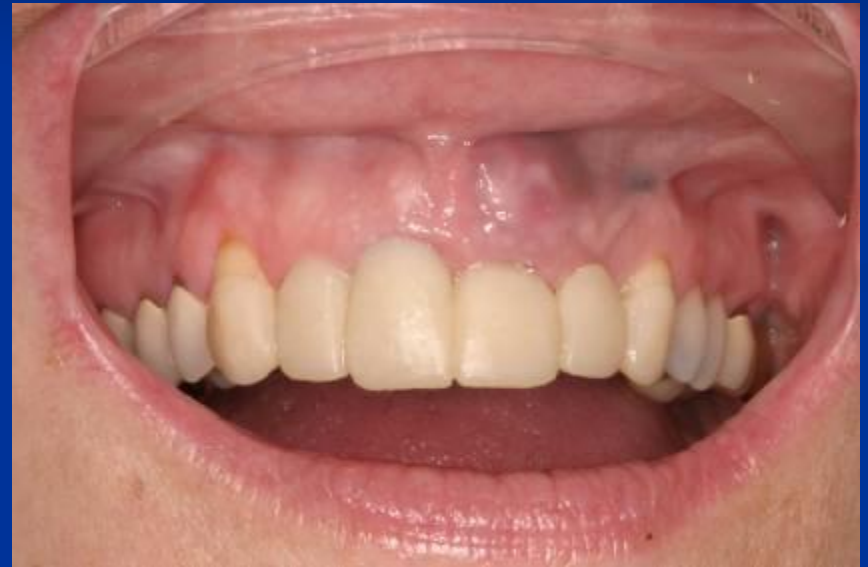16 days post op

- Attempt to tighten healing cap
- Pain!!!! Even with anesthetic

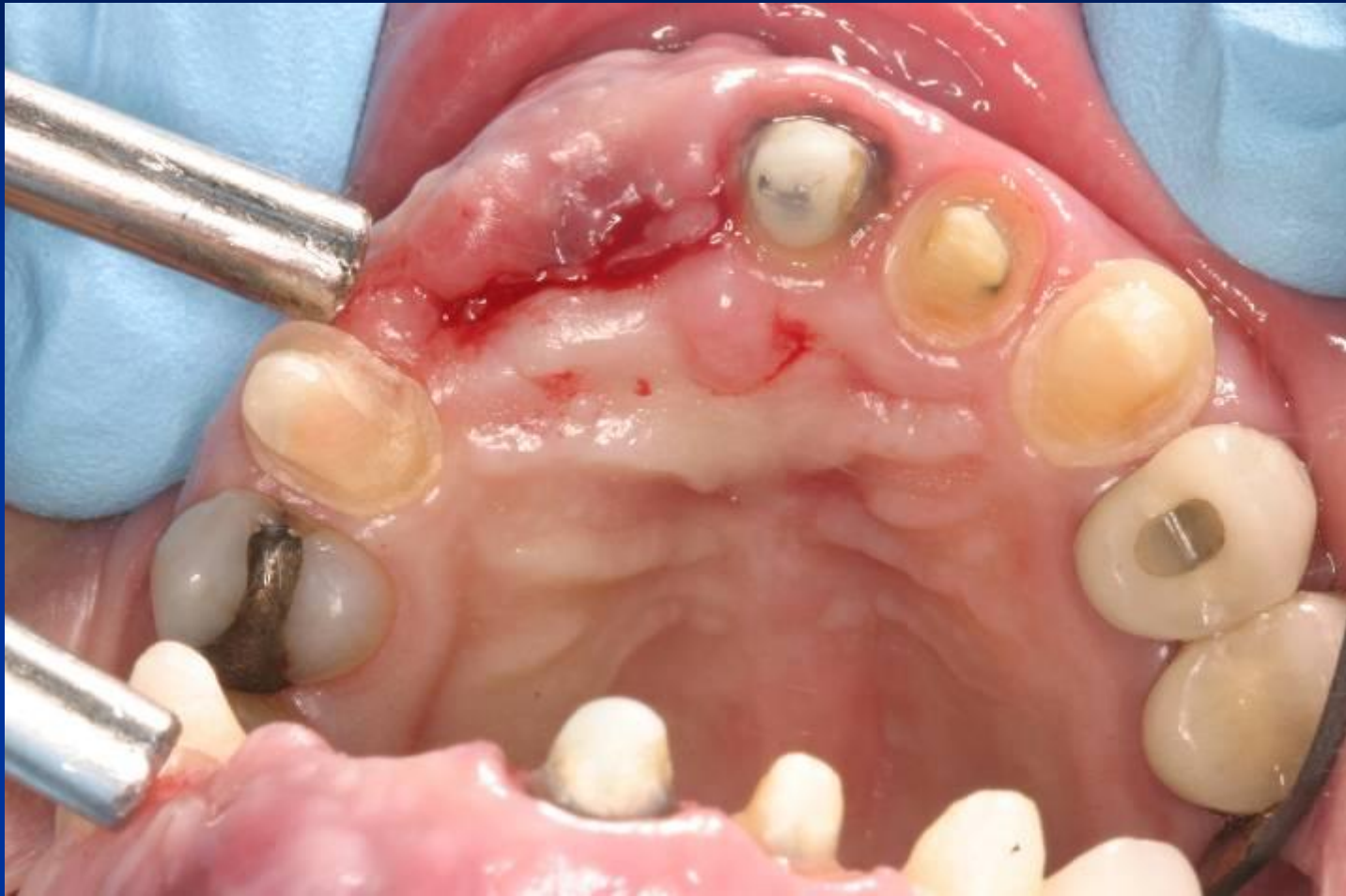

18 days post op

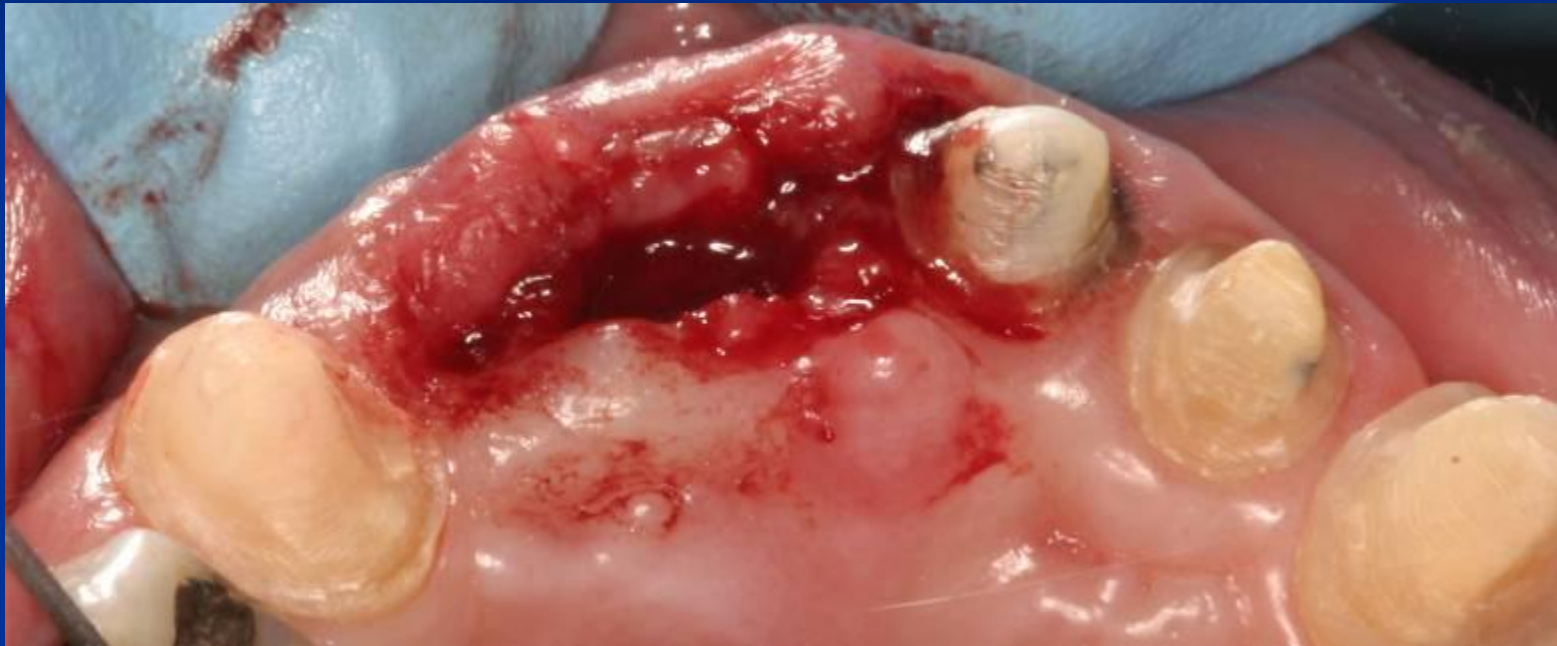- Continued pain
- Fluctuant swelling facial #9
- Consult with Dr. Leone, raise flap, push tissue to facial, replace healing cap with healing abutment



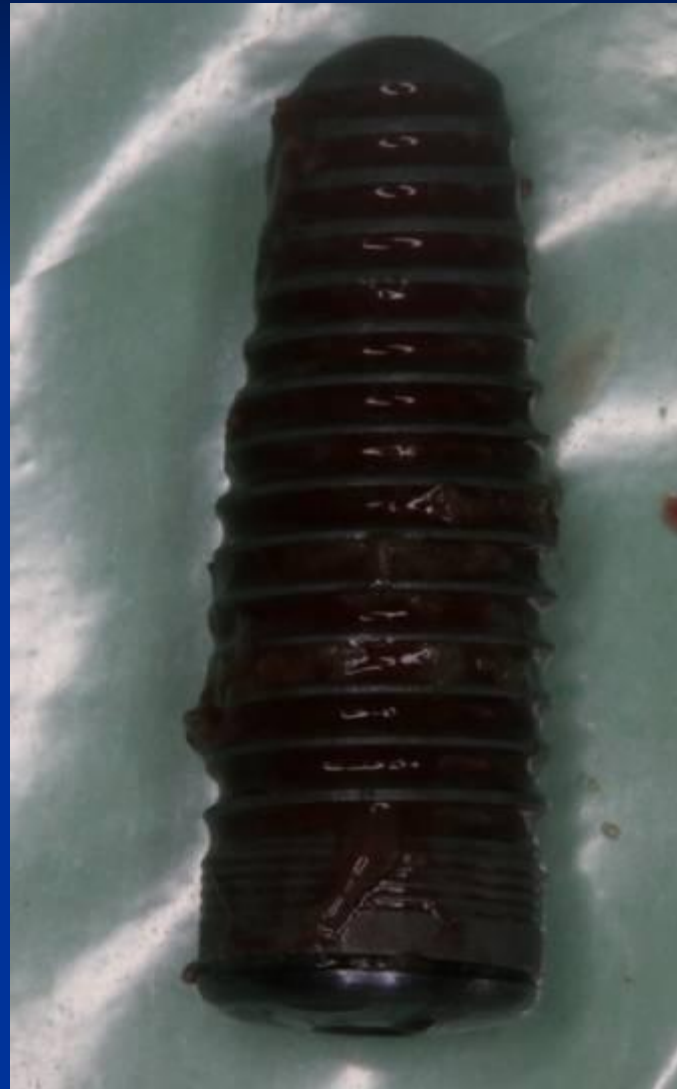18 days post op
Incision lingual to crest of ridge



18 days post op
Why does this look wrong?...

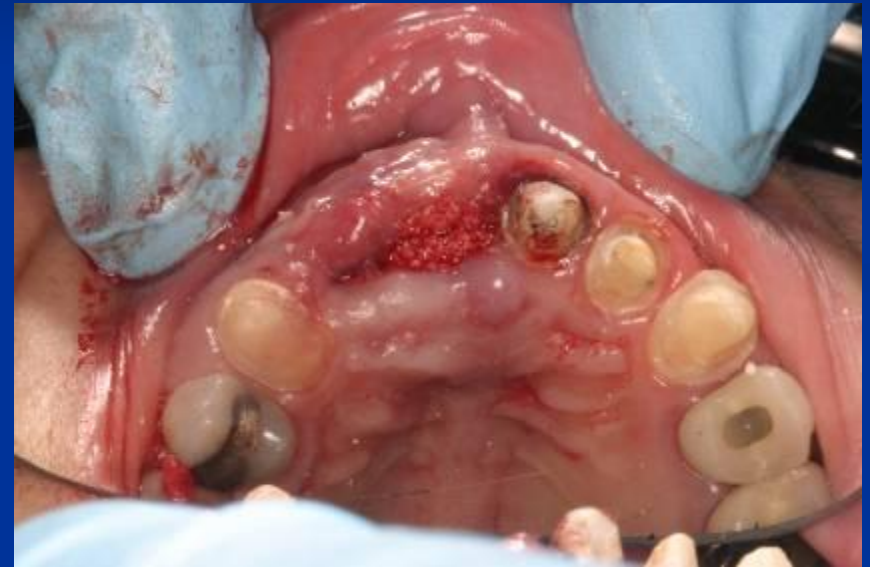

18 days post op
....Here is a hint

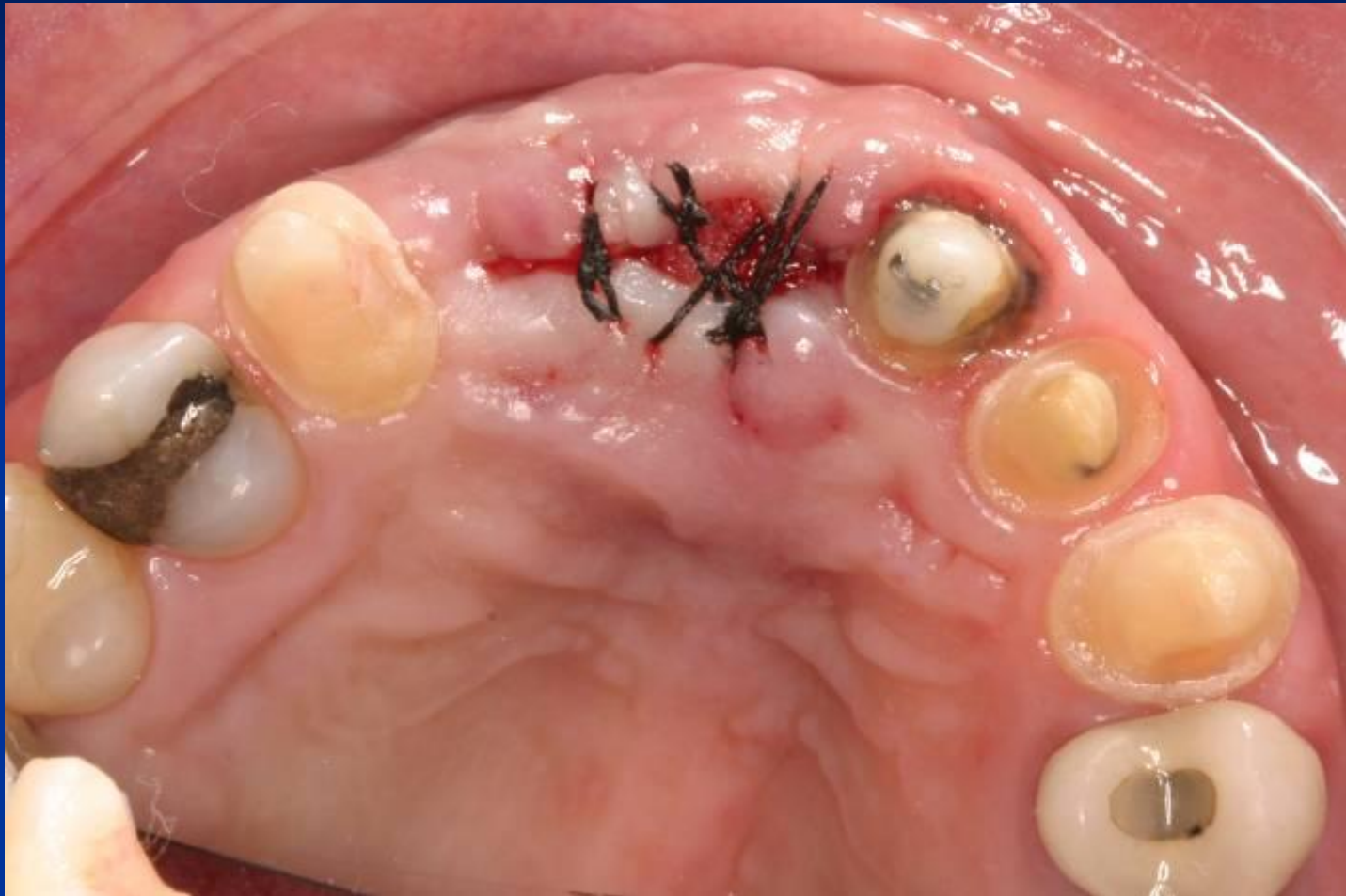

18 days post op

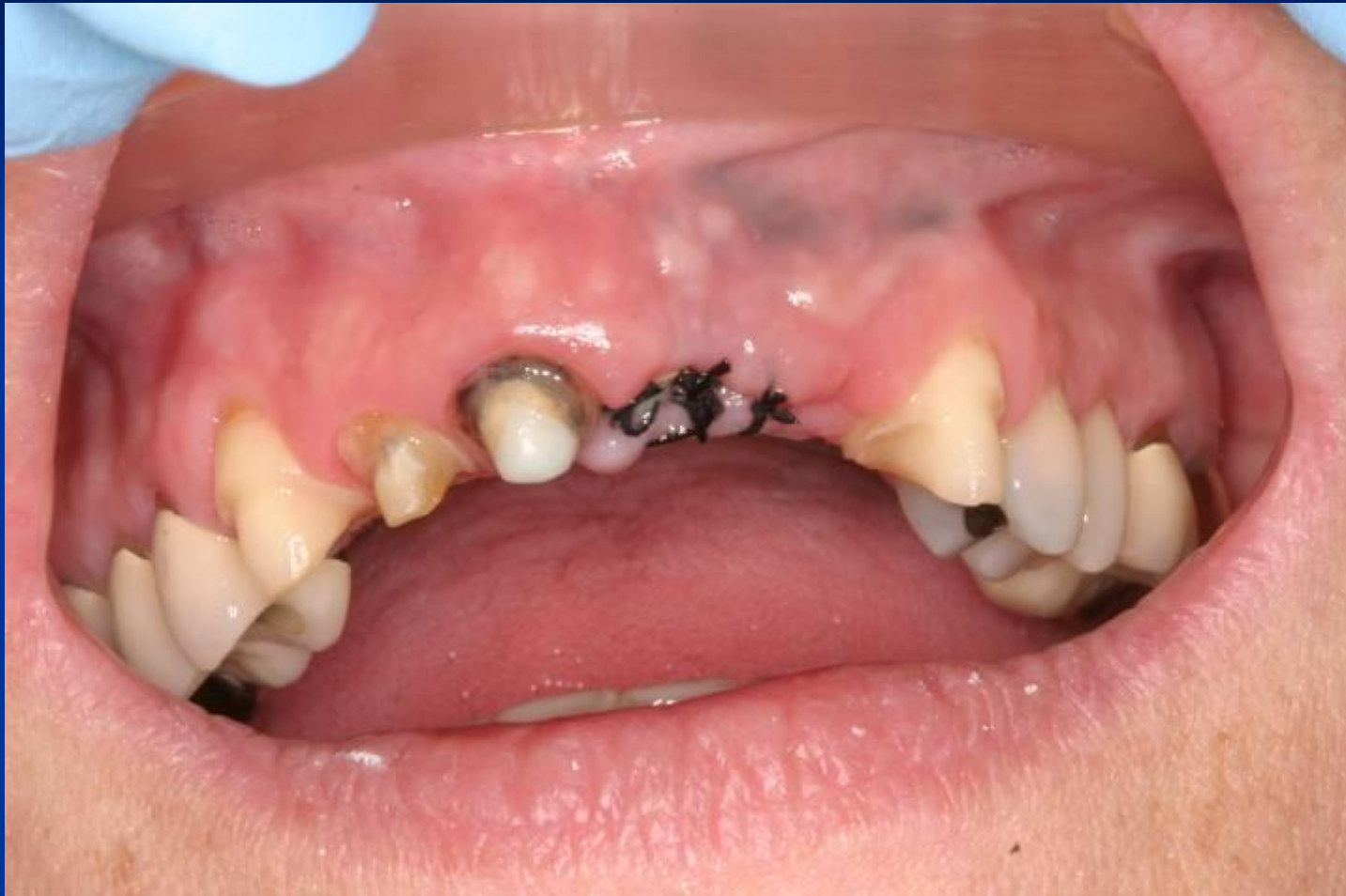- Socket debrided and evaluated
- Total loss of buccal cortical plate to apex of implant
- Placement of Puros graft and sutured shut



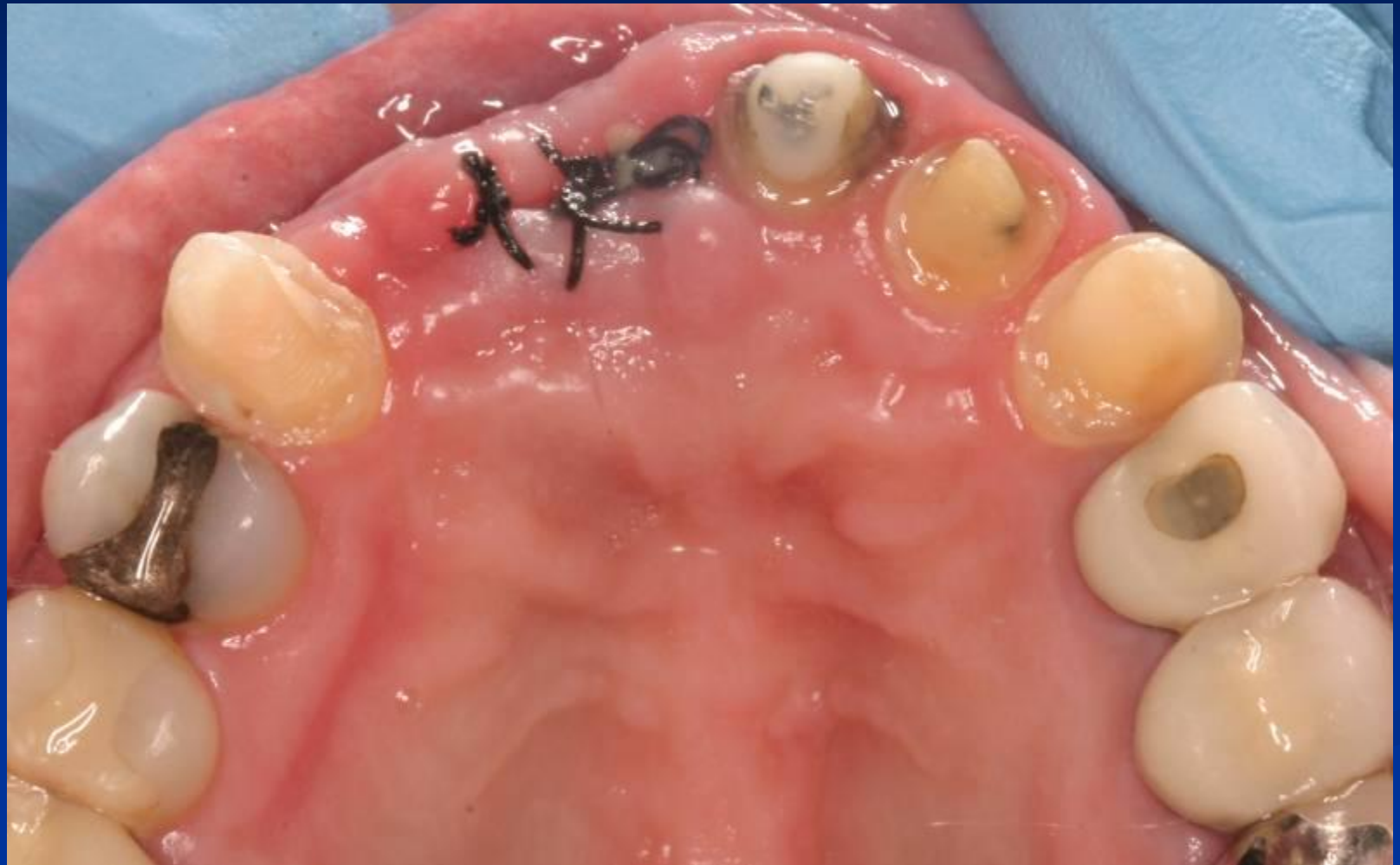18 days post op Sutures



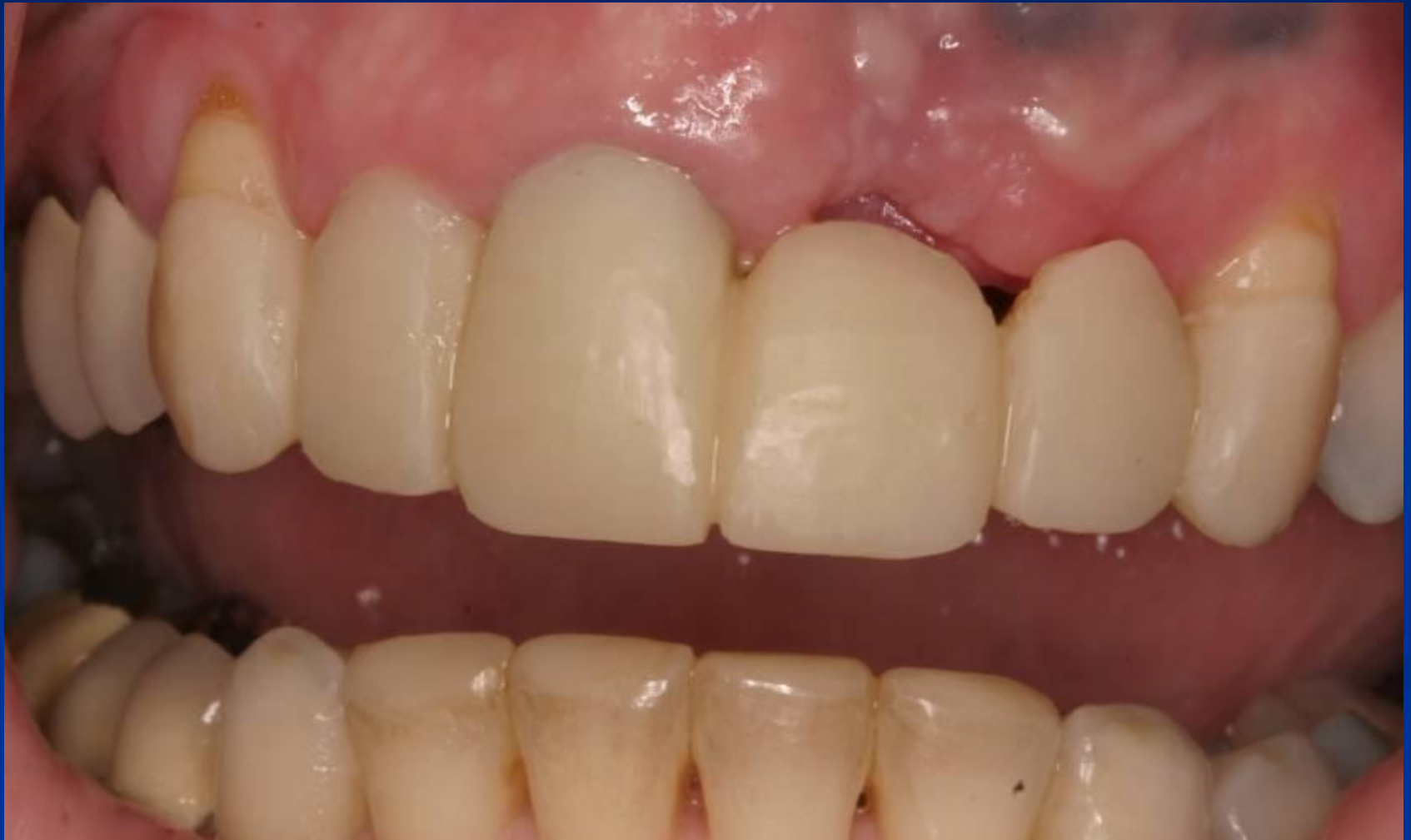25 days post op
tissue and ridge shrinking



25 days post op tissue and ridge shrinking

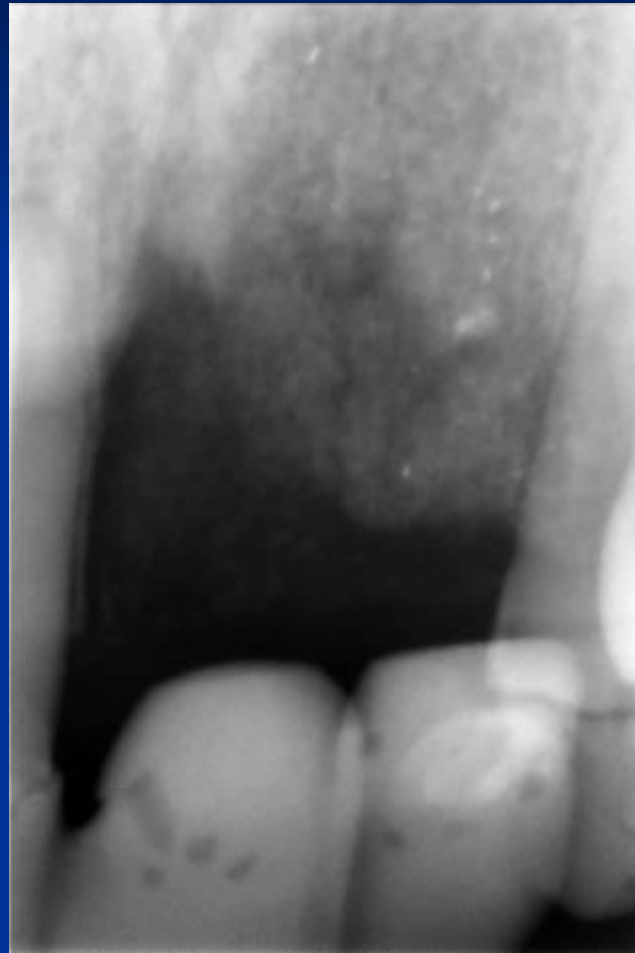


**32 days post op
tissue and ridge shrinking**

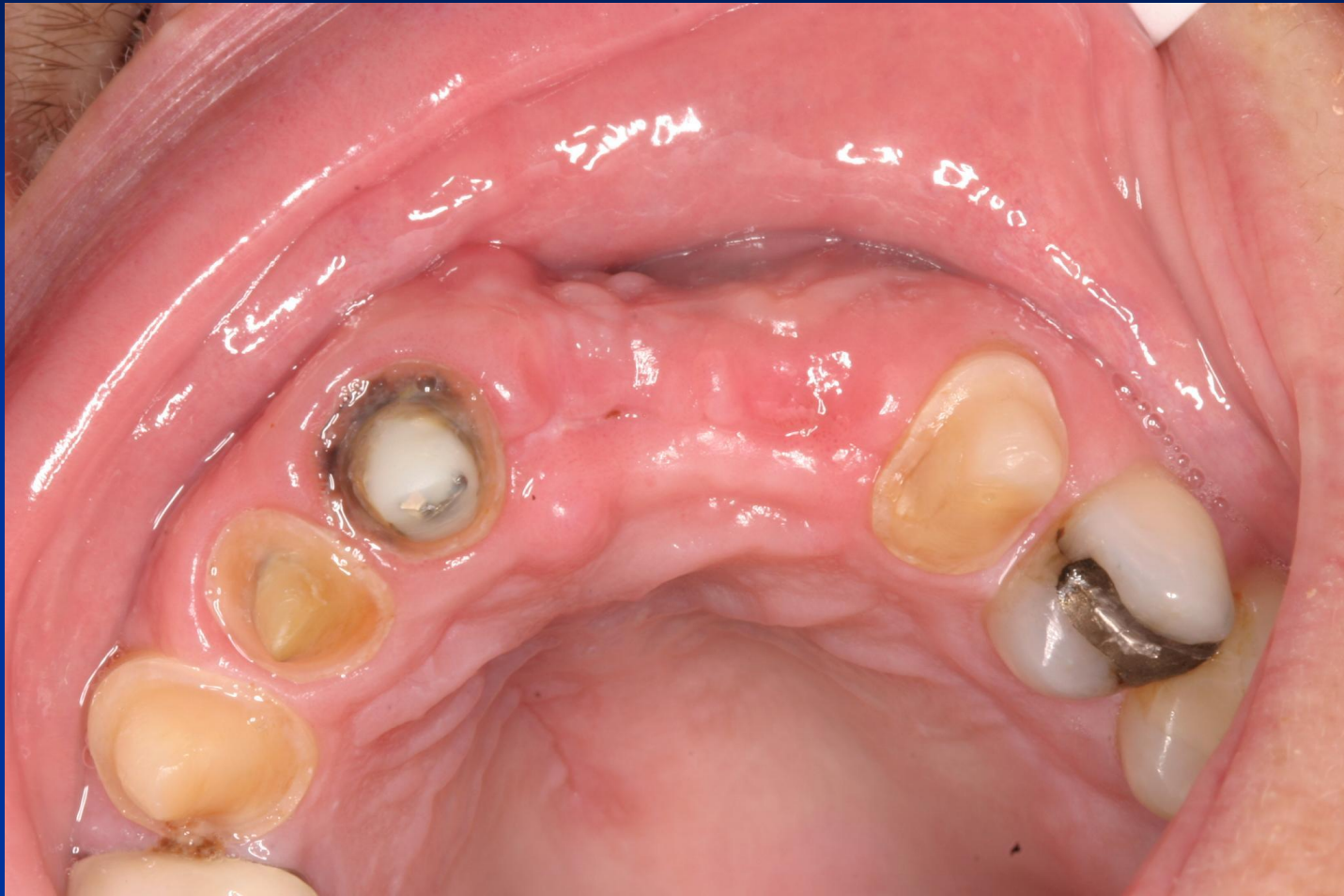

- Shrinking ridge with two grafted socket in the #9 and #10 sites
- RCT and post in #8
- Possible pulpal involvement of #11, it has been getting more and more sensitive throughout time of healing.
- Placement of implant in either #9 or #10 still an option?
- Where do I go from here?

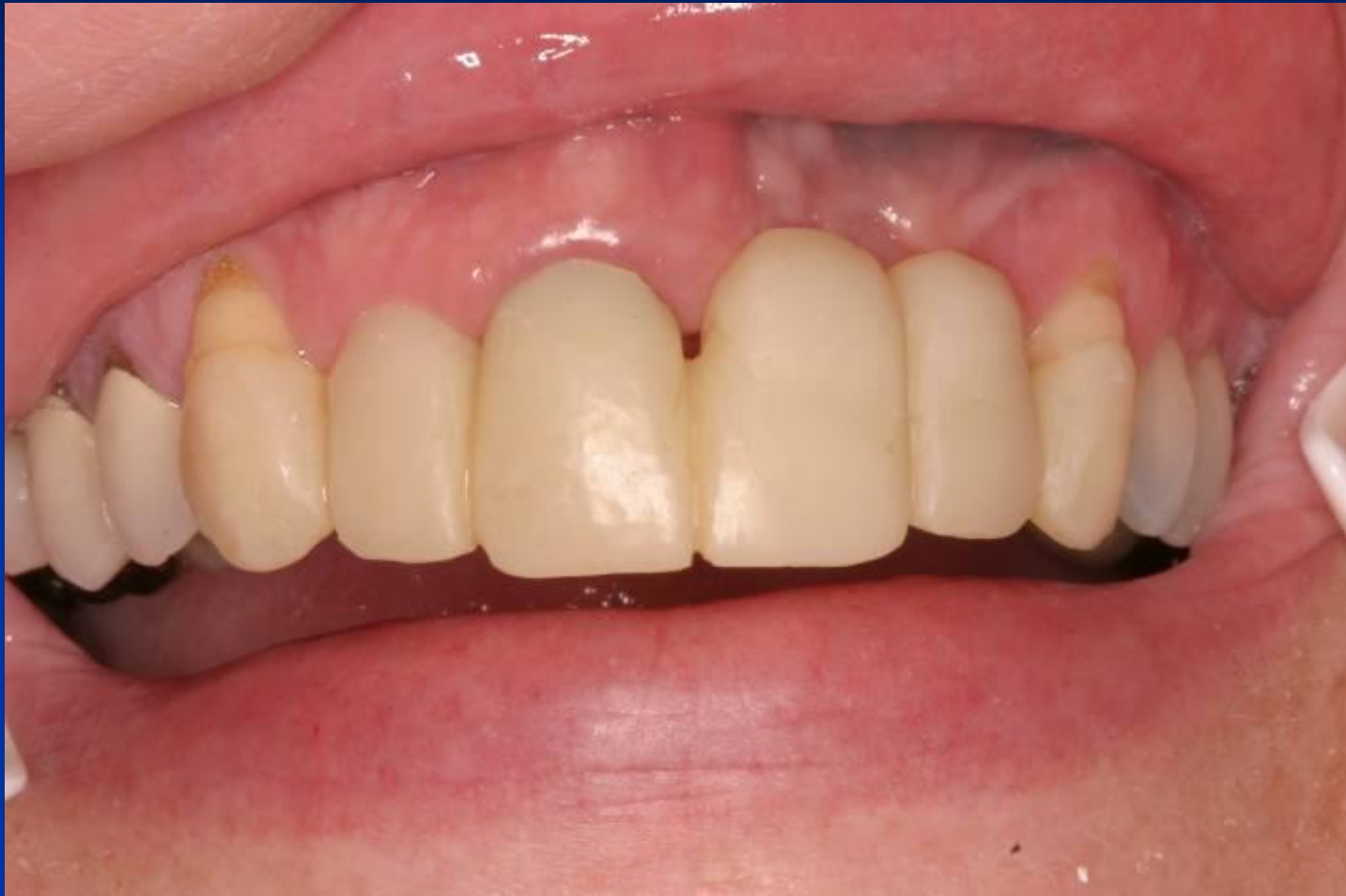November 15, 2008



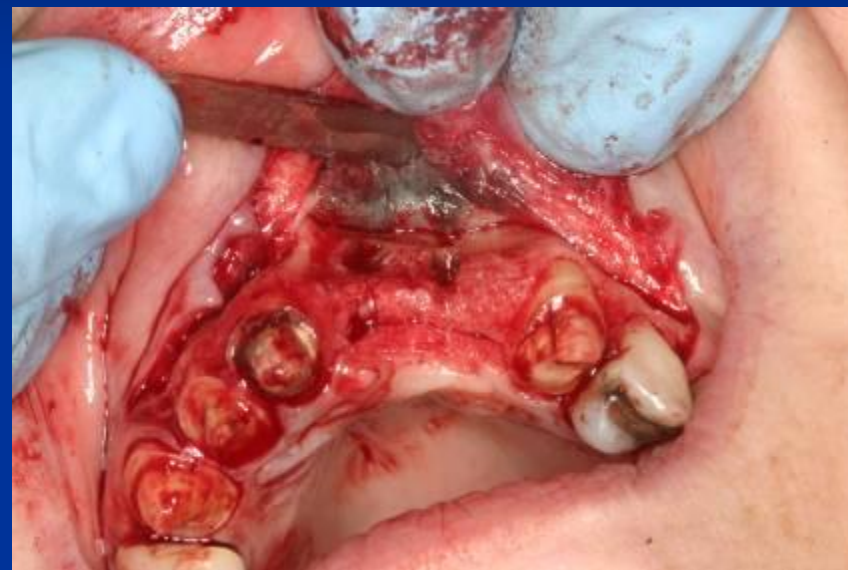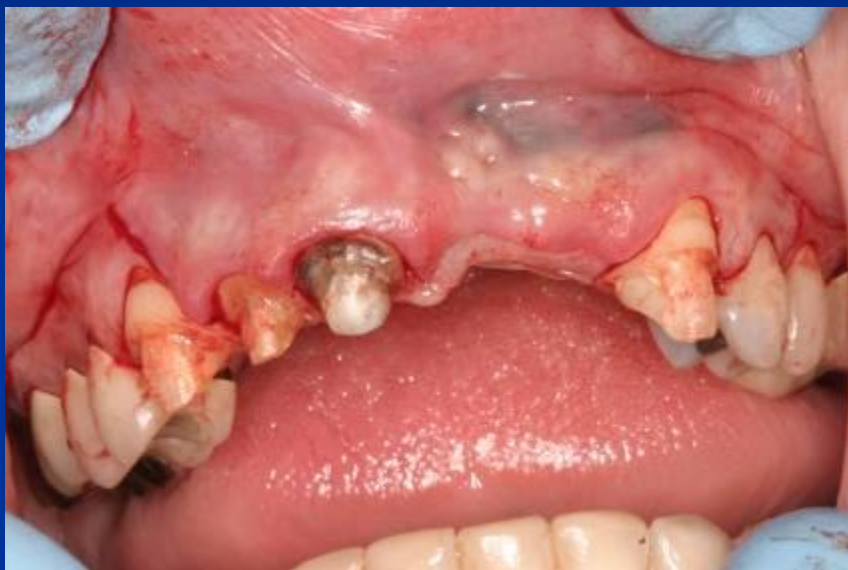November 15, 2008



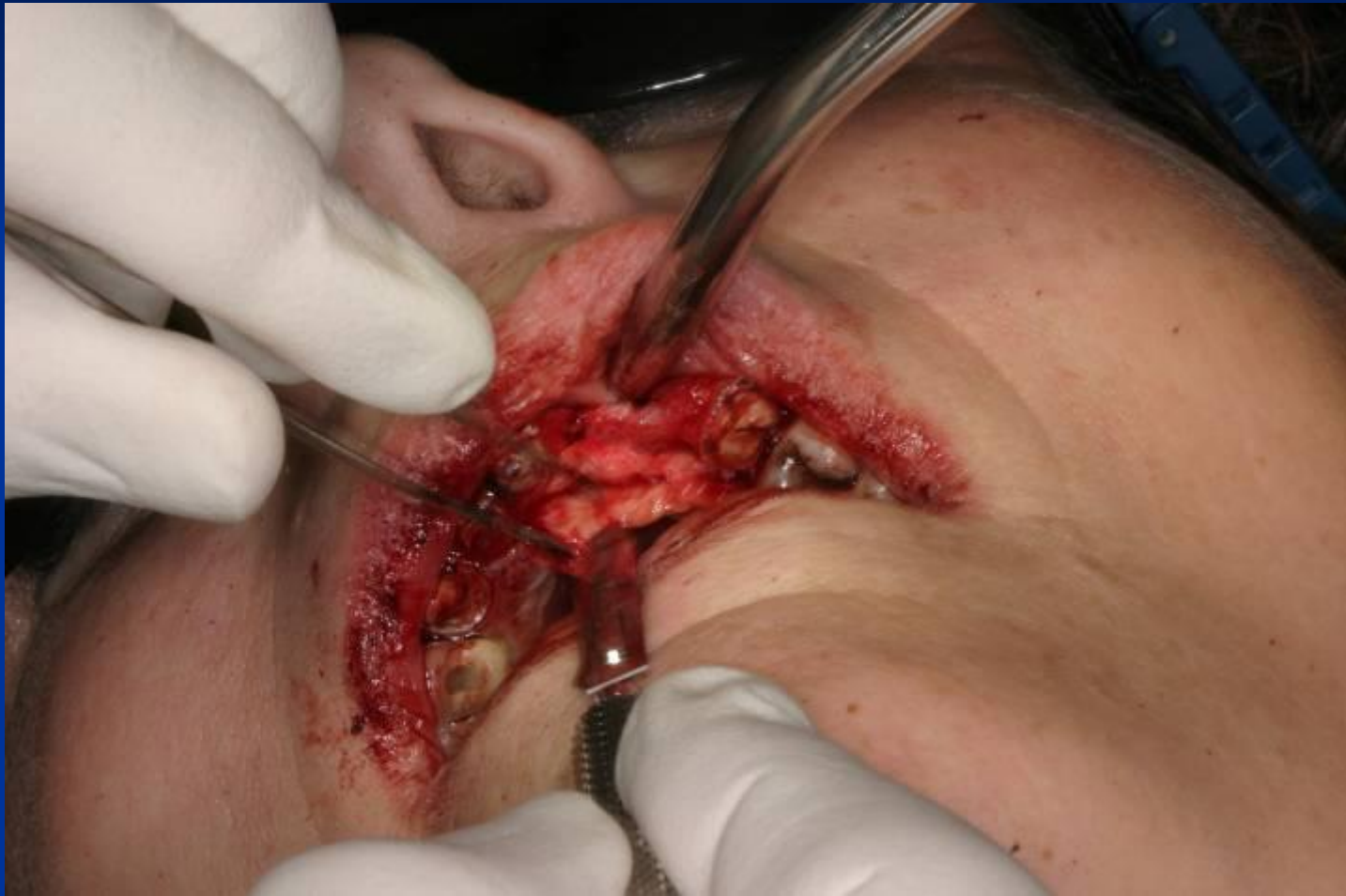November 15, 2008



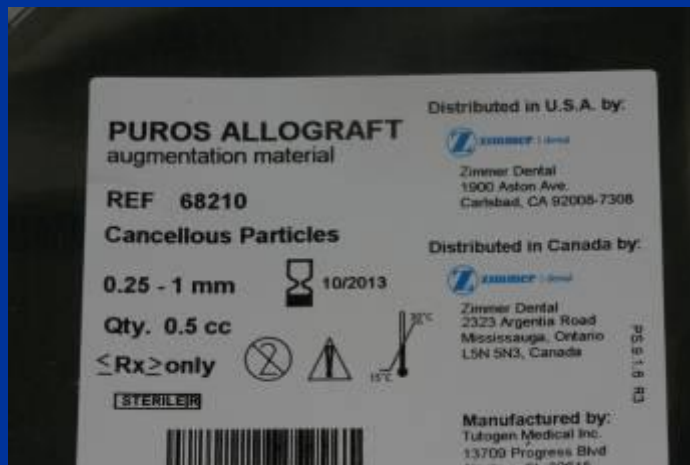

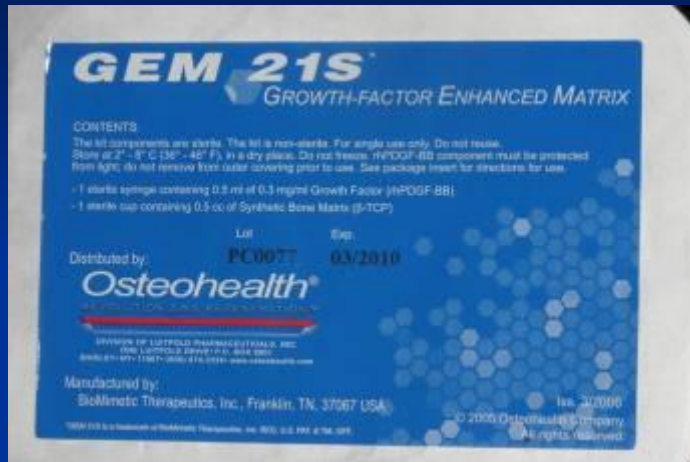
January 17, 2009



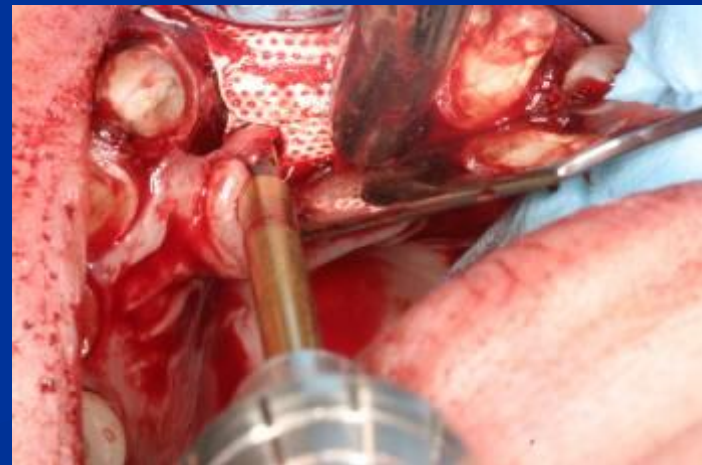

January 17, 2009



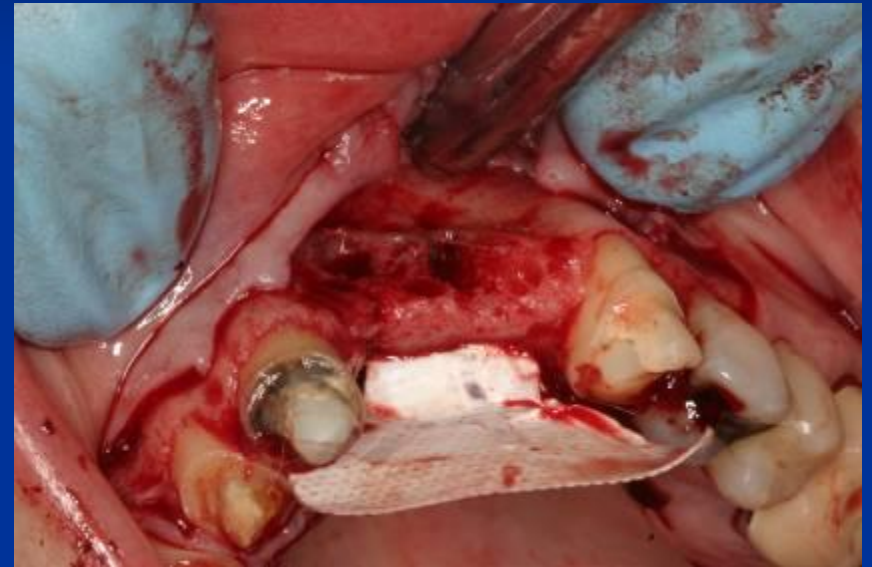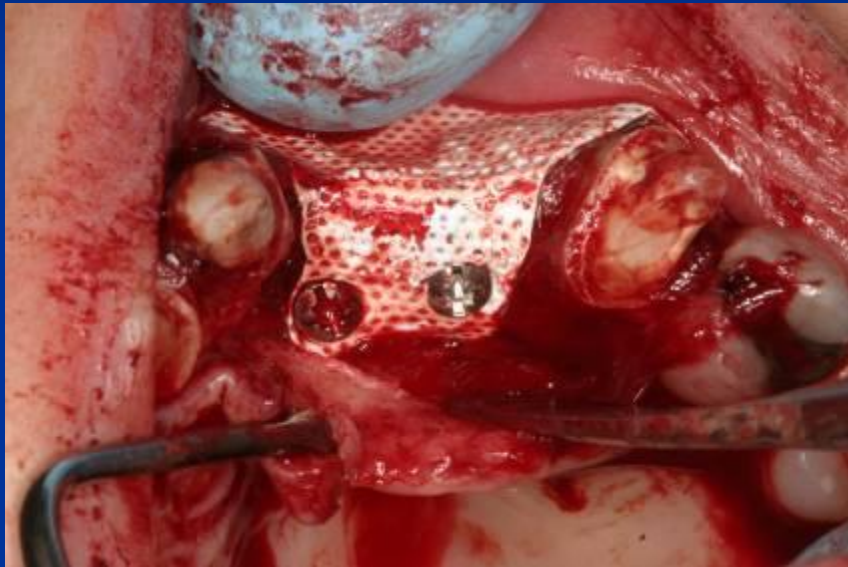
January 17, 2009



January 17, 2009

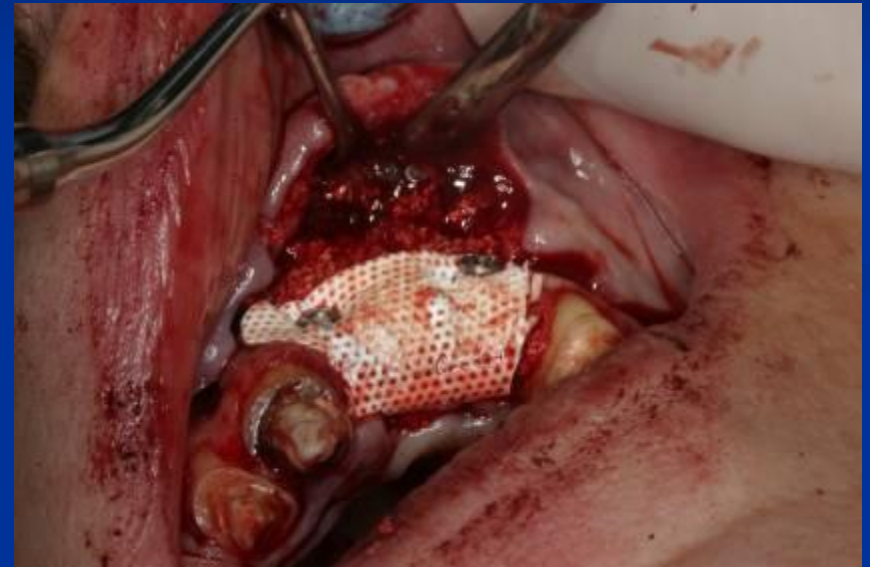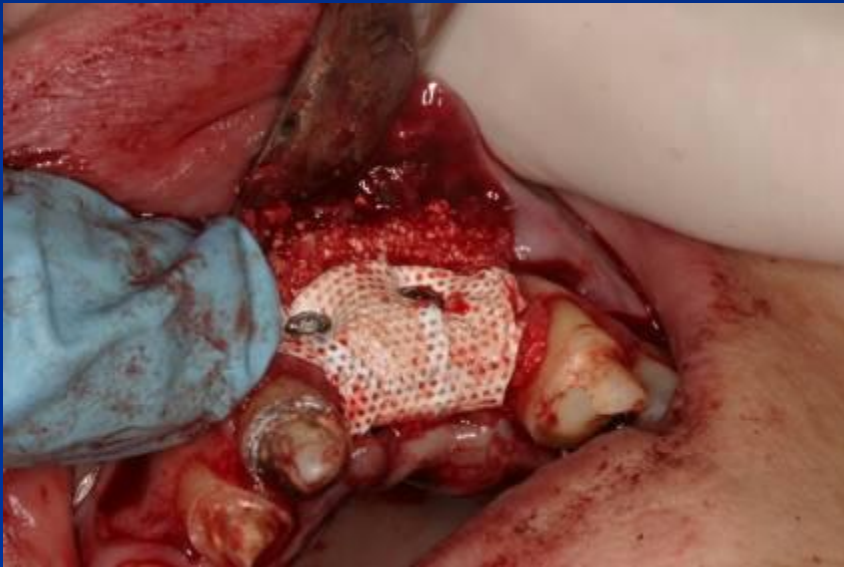


January 17, 2009

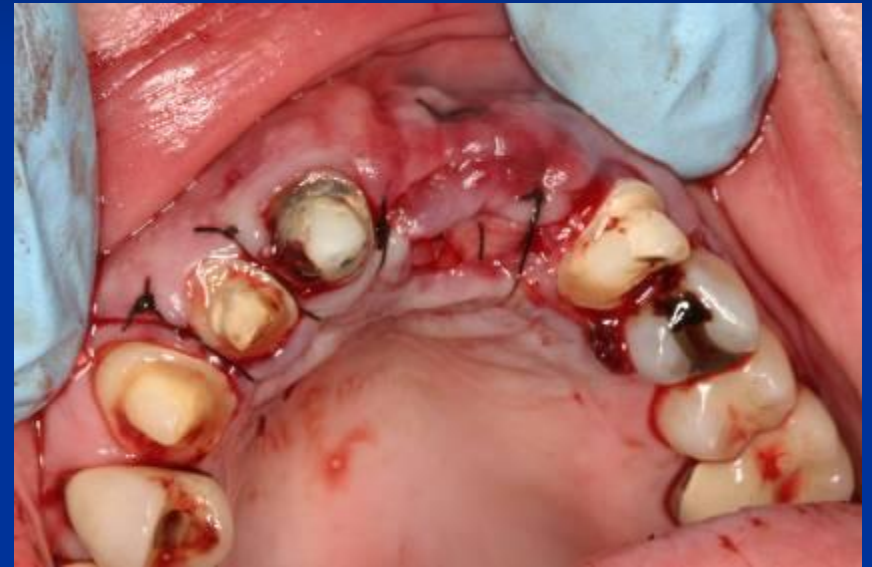
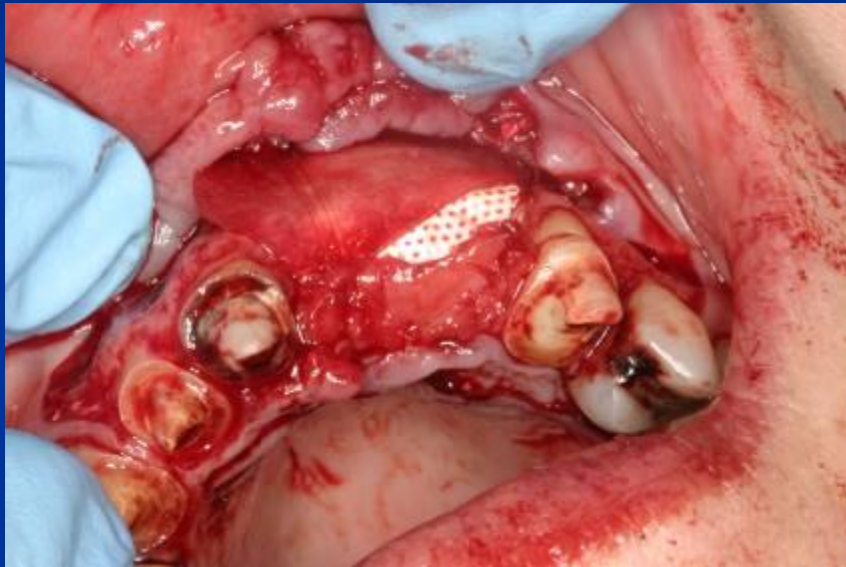
January 17, 2009

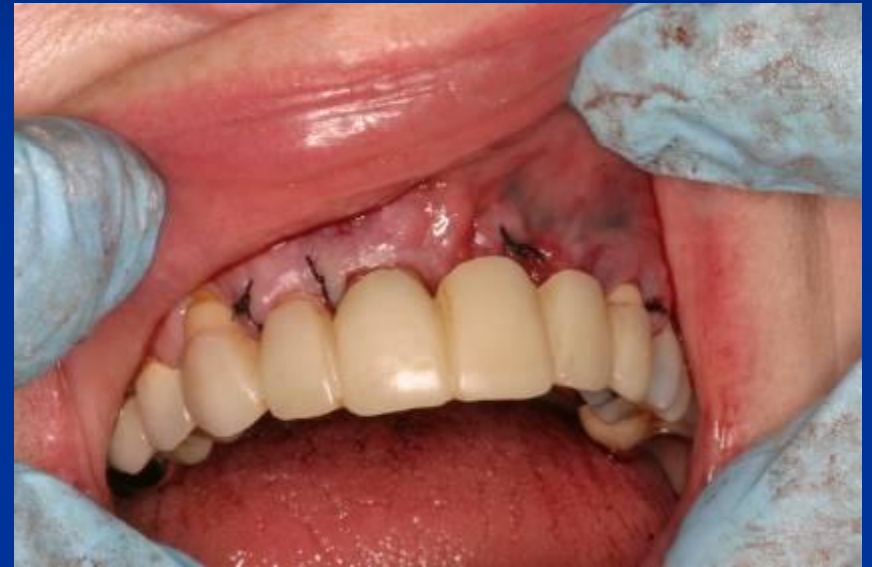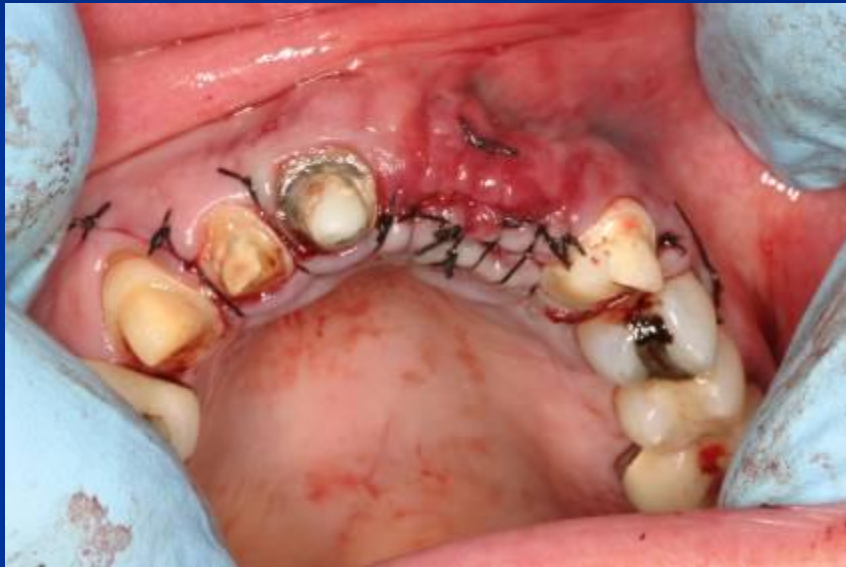placed bone screw but then moved position to not constrict the membrane



January 17, 2009



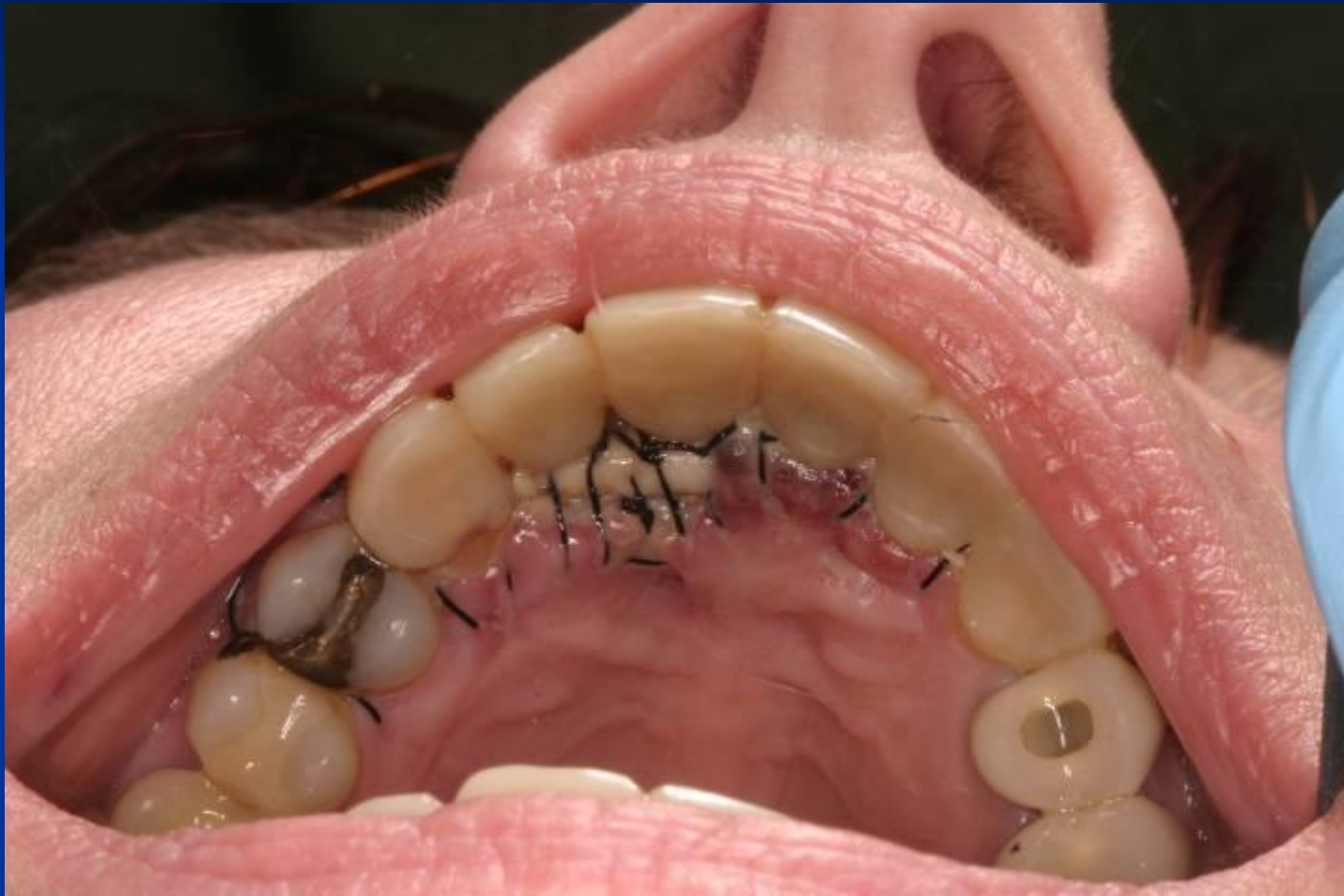January 17, 2009



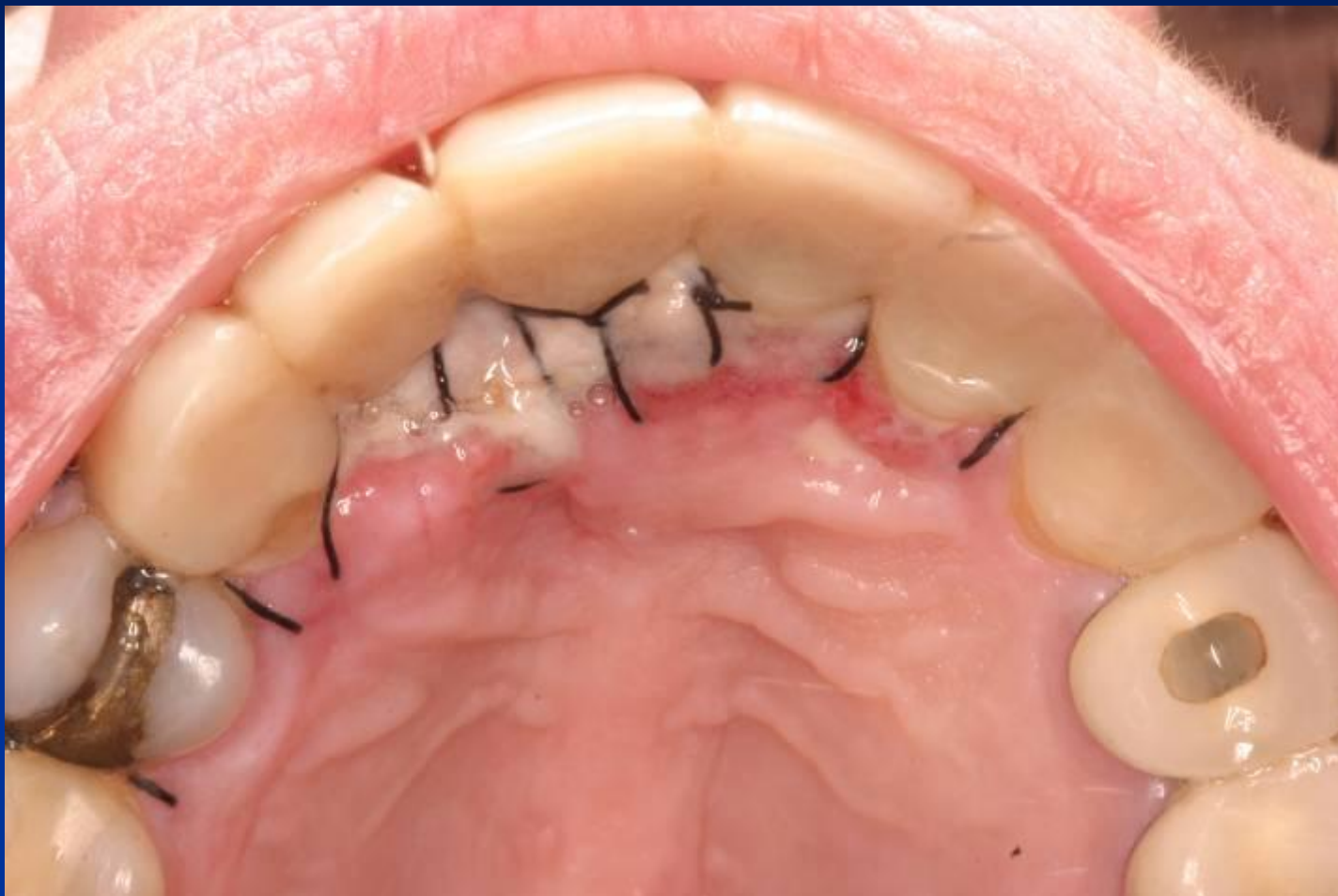January 17, 2009

- Post Op meds
 - Augmentin 500mg BID
 - Ketoprophen 75mg Q6H
 - Medrol decreasing dose pack
 - Vicodin 5mg 1 Q4-6H

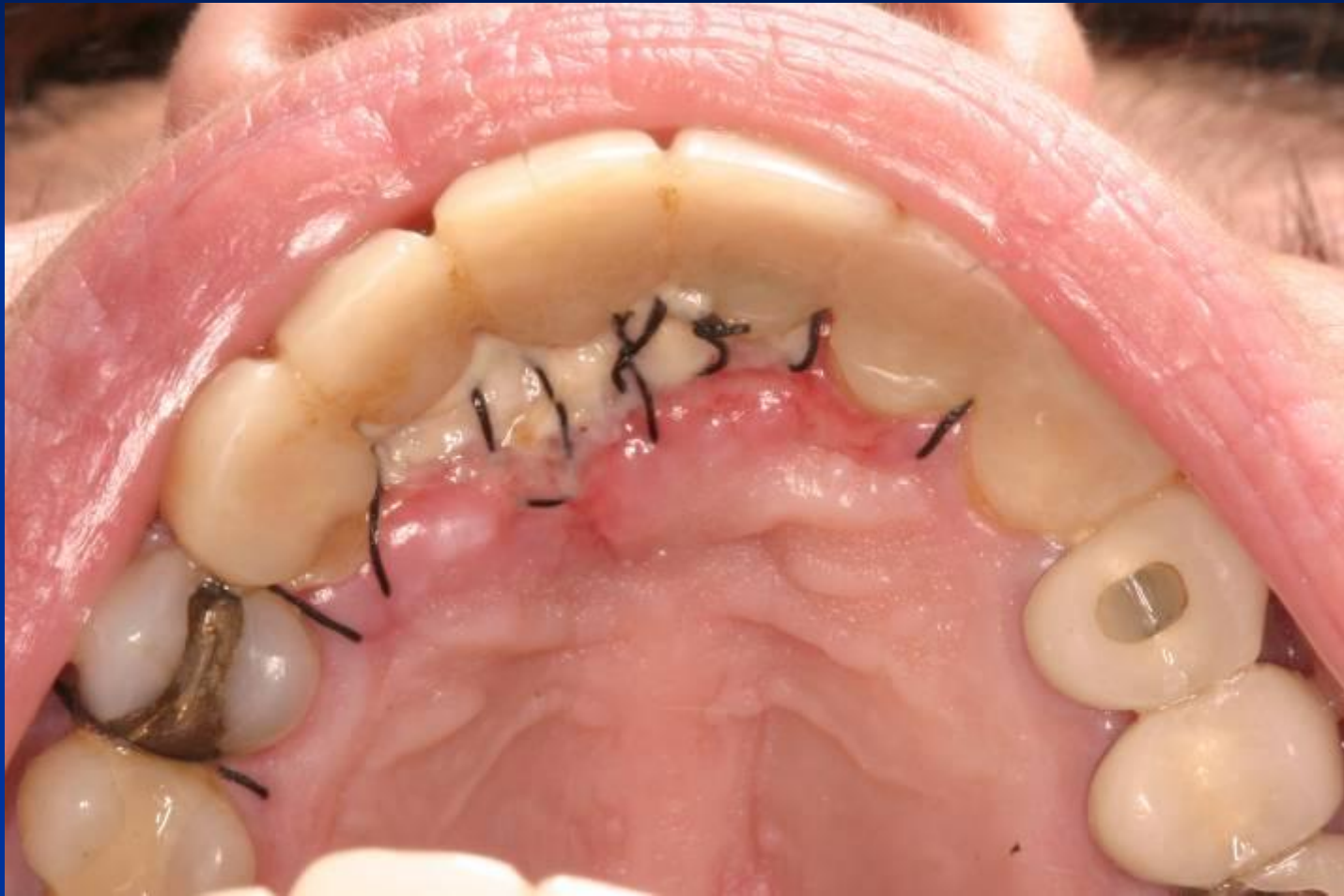January 19, 2009
Two days post op



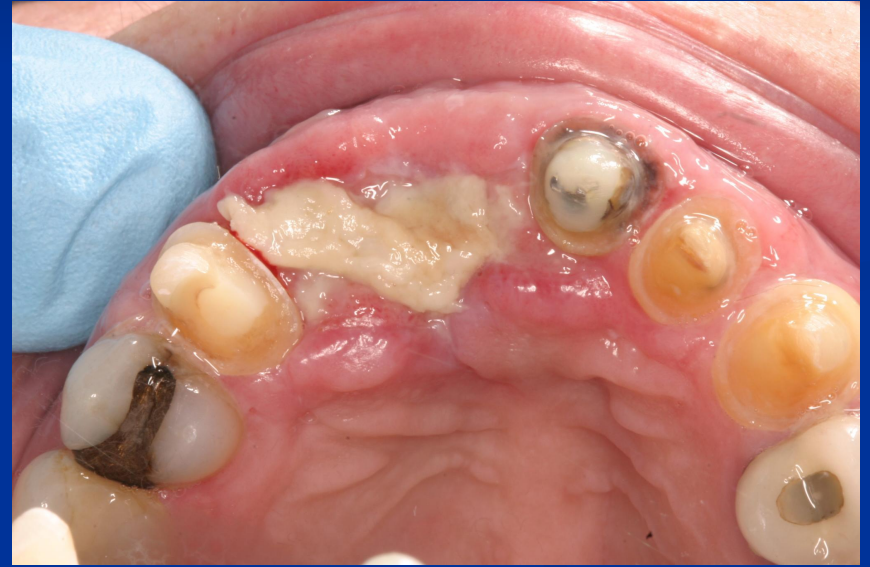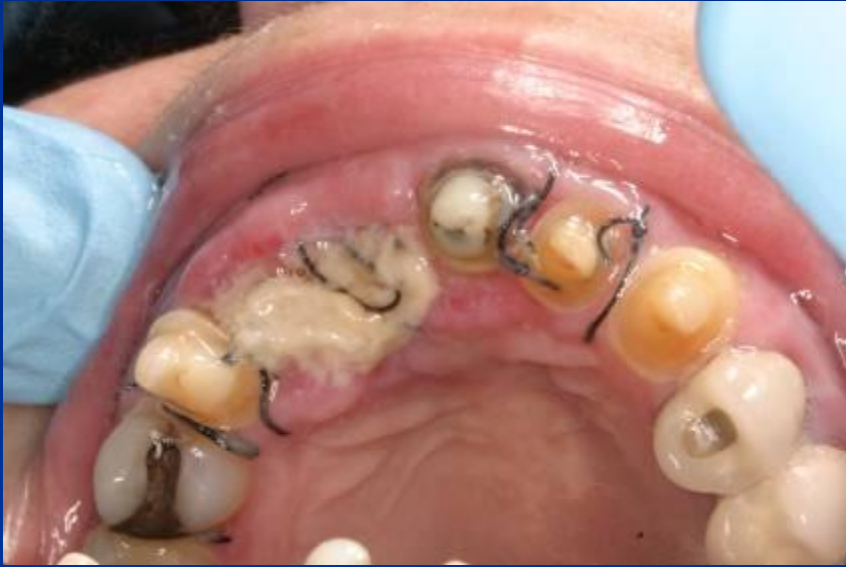January 20, 2009
Three days post op



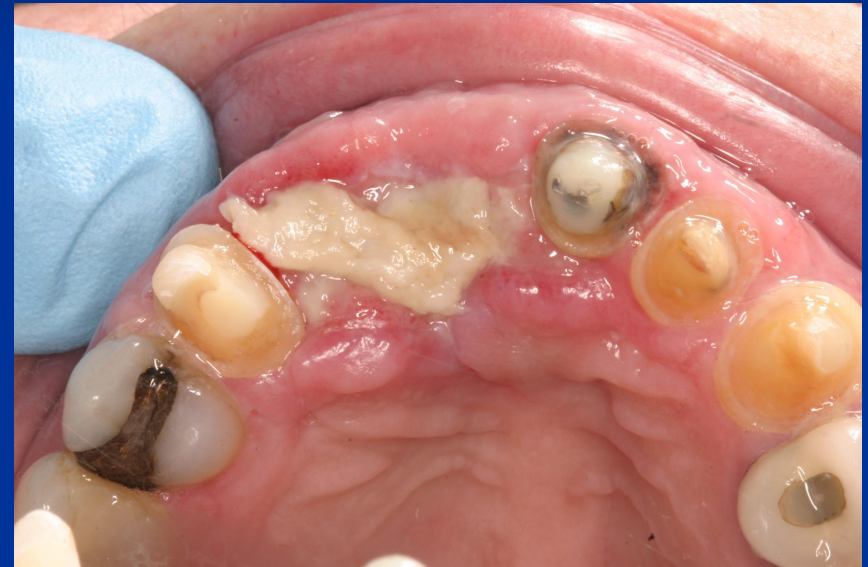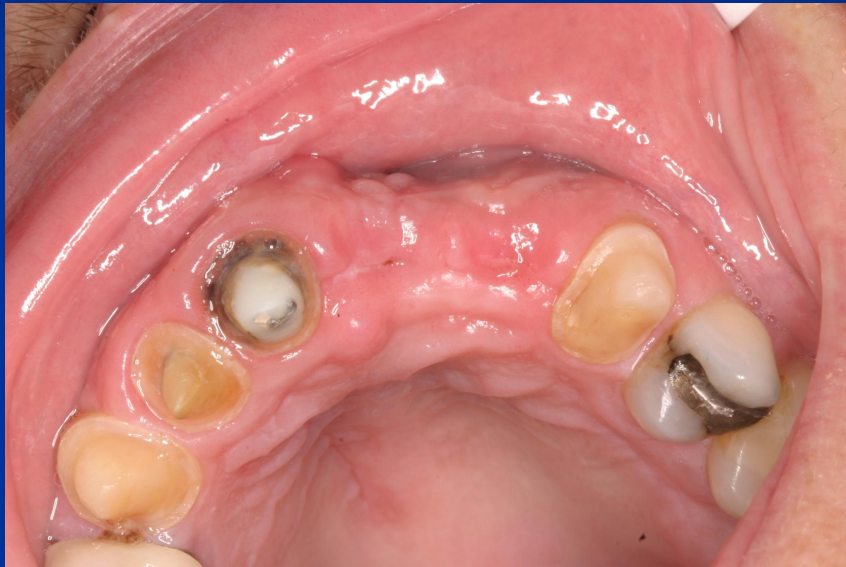January 22, 2009
Five days post op



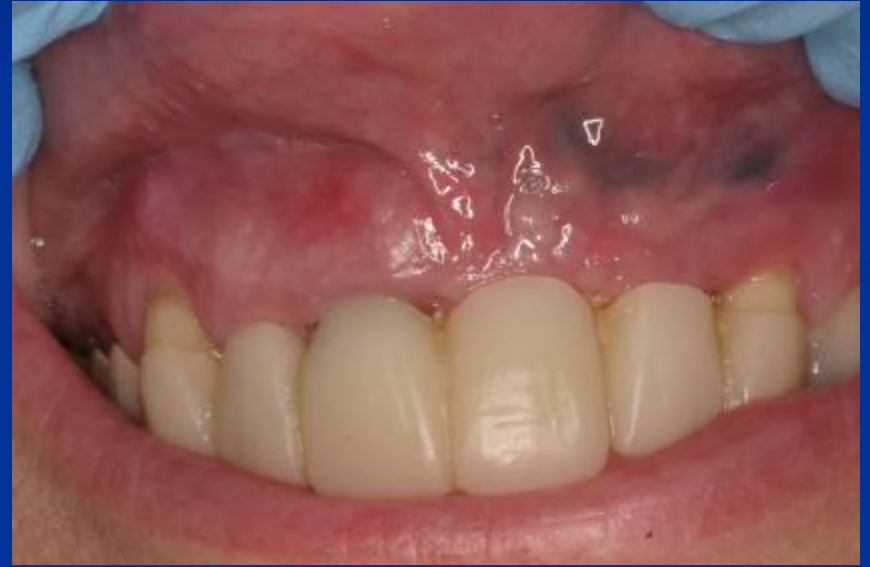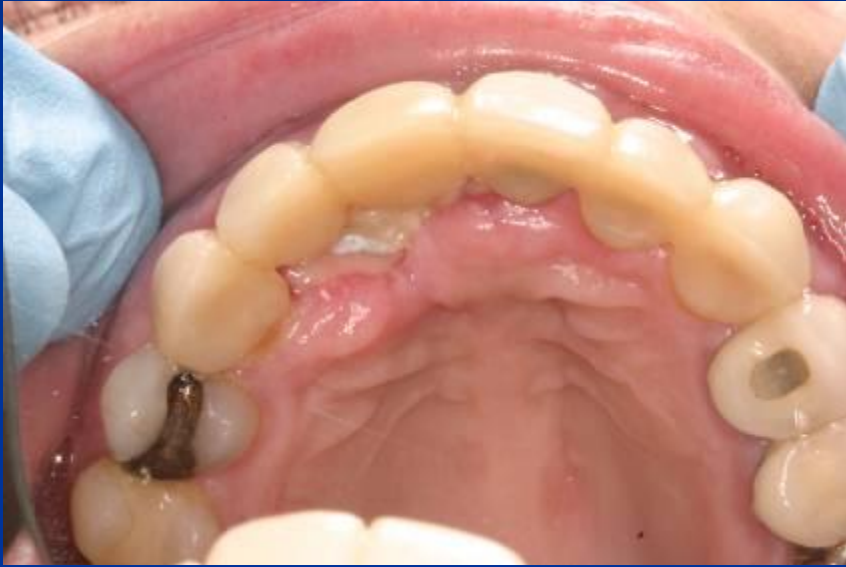January 29, 2009
12 days post op



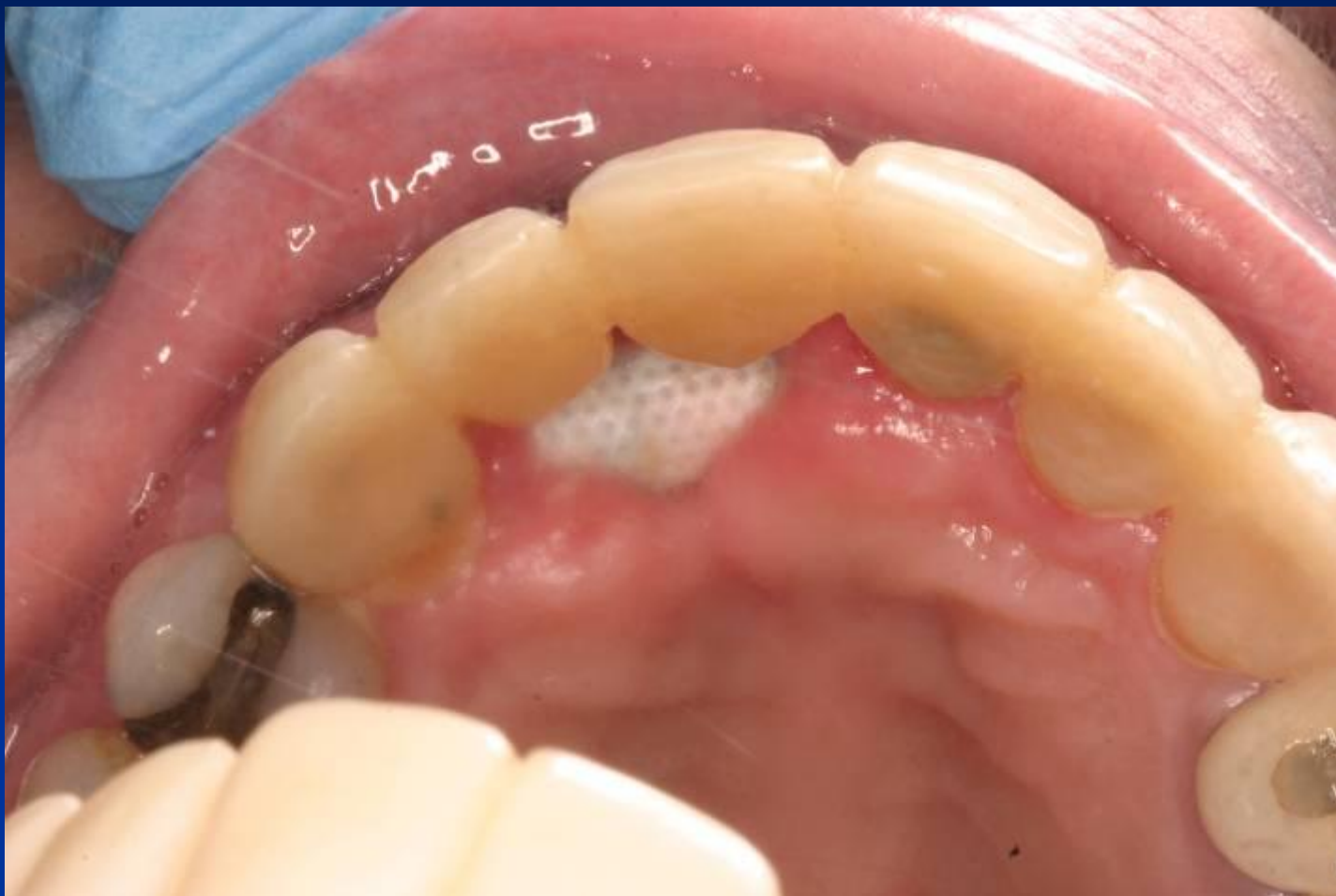Preop vs. Suture Removal (12 days post op)



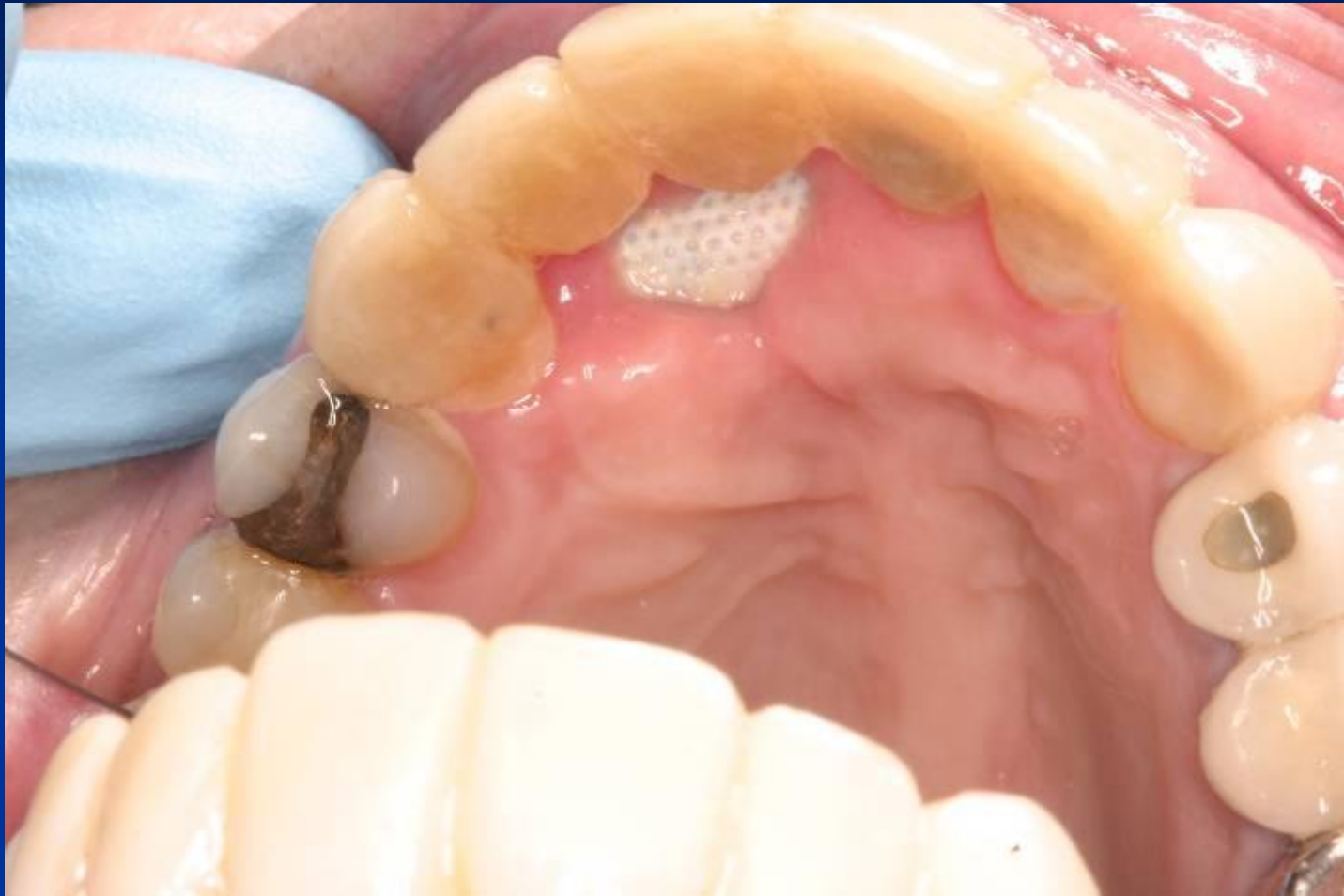February 2, 2009
Two weeks post op



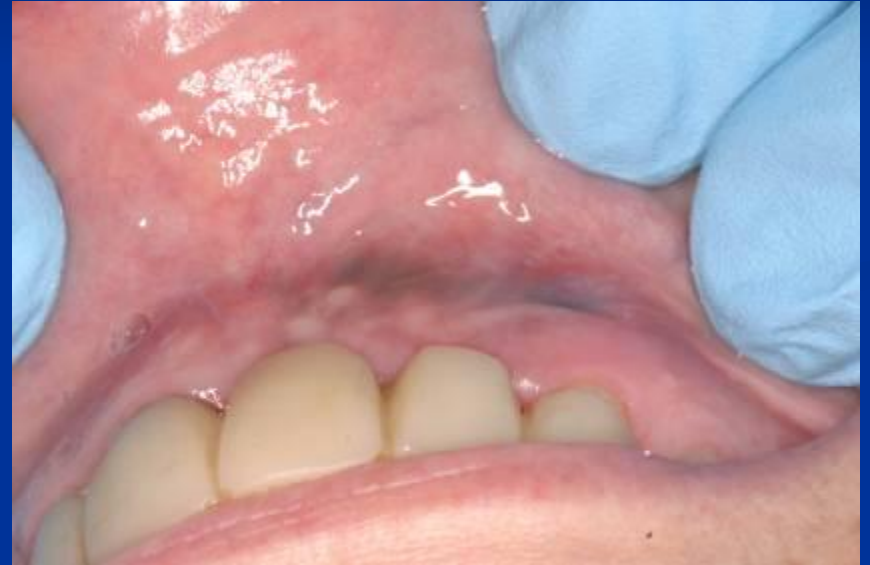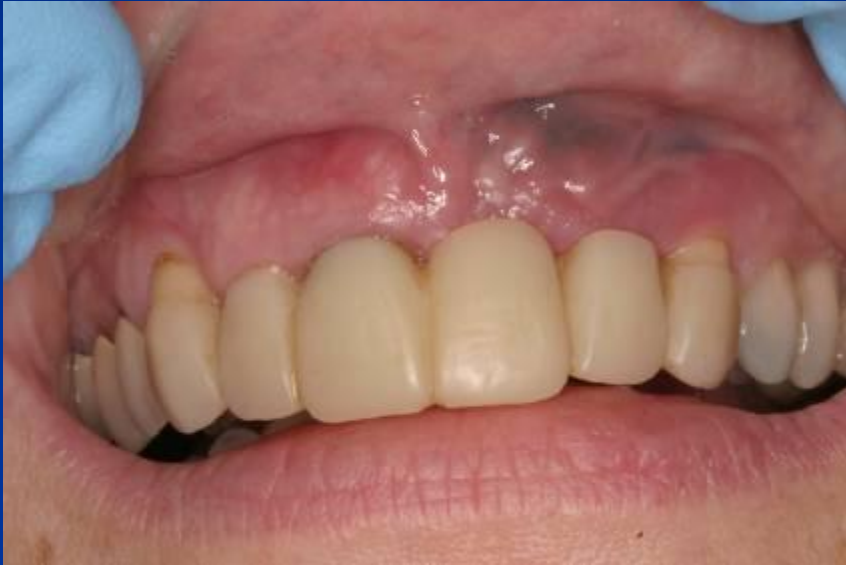February 11, 2009
Four weeks post op



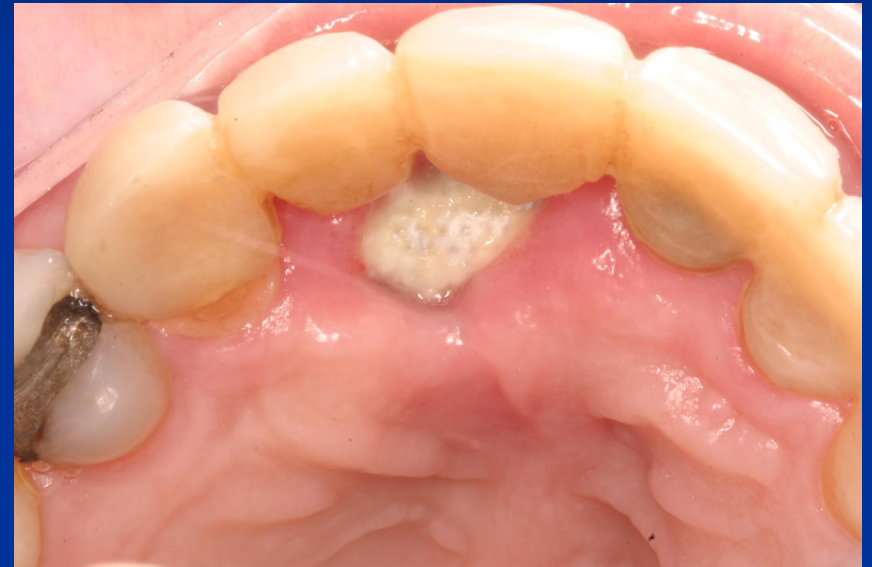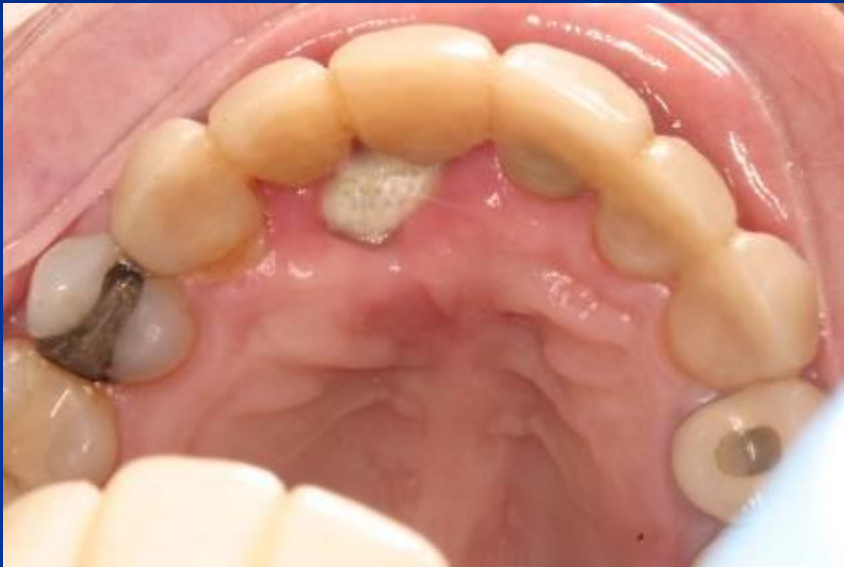February 19, 2009
Five weeks post op



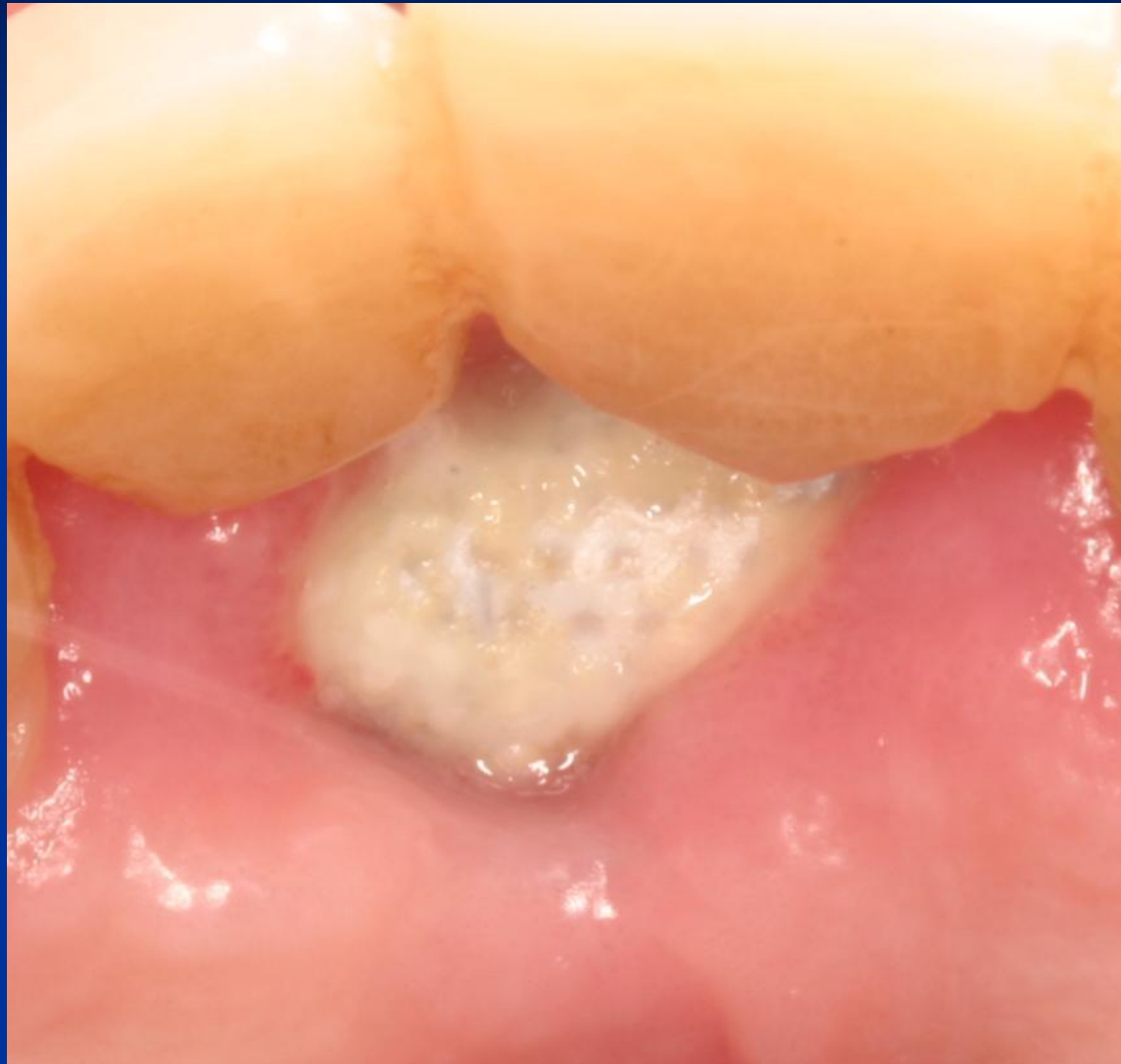March 5, 2009
Seven weeks post op



March 5, 2009
Seven weeks post op



March 5, 2009
Seven weeks post op



- Presented with #10 fractured off at the gingival level in October of 2006
- Ortho until August of 2008
- First study club surgery September of 2008. EXT #9 and #10, socket repair #10, placement of 5.0mm implant in #9 site.
- Loss of implant in October of 2008.
- Loss of vitality of #11 in December 2008, RCT completed.
- Second study club surgery January 17, 2009.
- Expected time to uncover and place implant July/August of 2009.

- Phone conversation March 20, 2009
 - Ibuprofen 3 times per day
 - Without medication surgery site gets “achy and throbbing” but seems to be lessening lately and can put more time between Ibuprofen dosages
 - Woke one night with blood in her mouth in past two weeks
 - Very tender to touch
 - Rinses with water when food debris gets caught in site
 - Peridex since the surgery two times per day