# Lateral Wall Sinus Lift

KCMcVey DDS and Jason Han DDS

IEPSC Sept 2022

Patient: Don W.
RMH: no contraindications to tx
-hx of a-fib
-hx of HTN
- metoprolol, lisinopril, pradaxa
-prob undiagnosed OSA and reflux
Well maintained oral health other than severe attrition/erosion

Jason recently completed full maxillary arch rehab: VDO was increased approximately 2mm

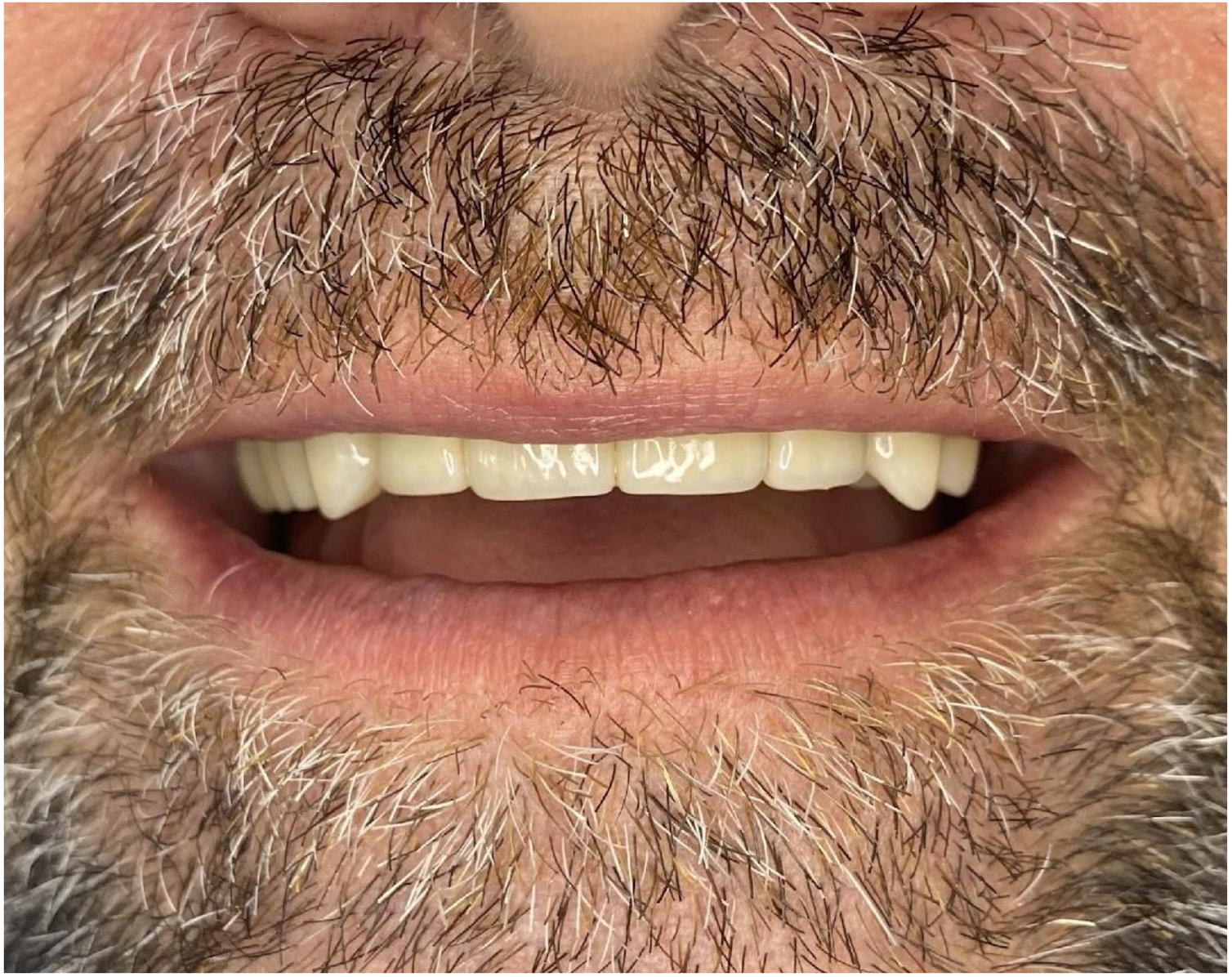

Yes Don has "bear" teeth

# Sinus Augmentation UL

- Goals:
- place implant at #13
- Augment sinus
- Possibly simultaneously place implants #14 and #15

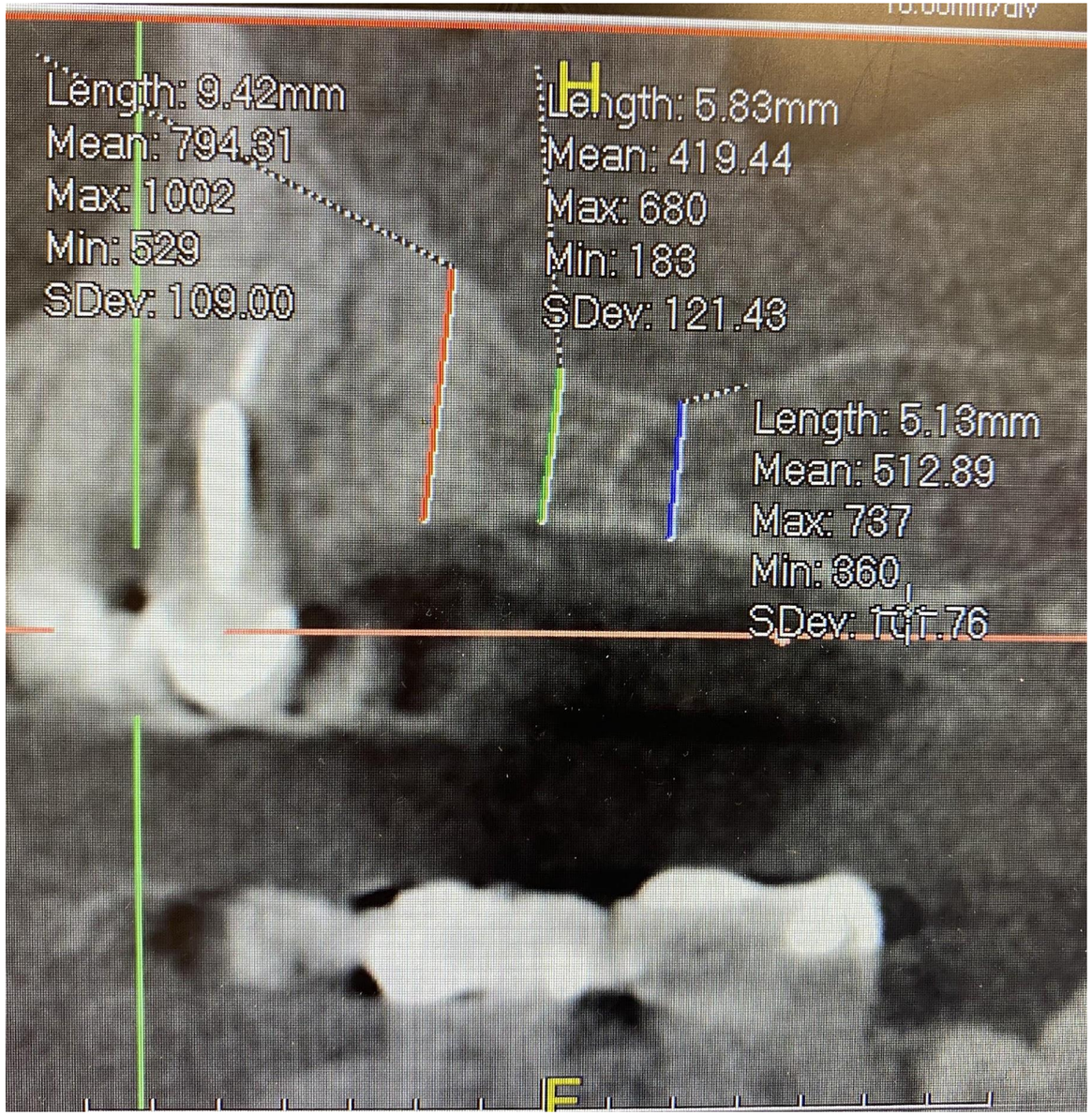

# Concerns

- Available bone for simultaneous placement of implants
- Thickness of schniederian membrane: pathologic?
- Guarded prognosis of #12

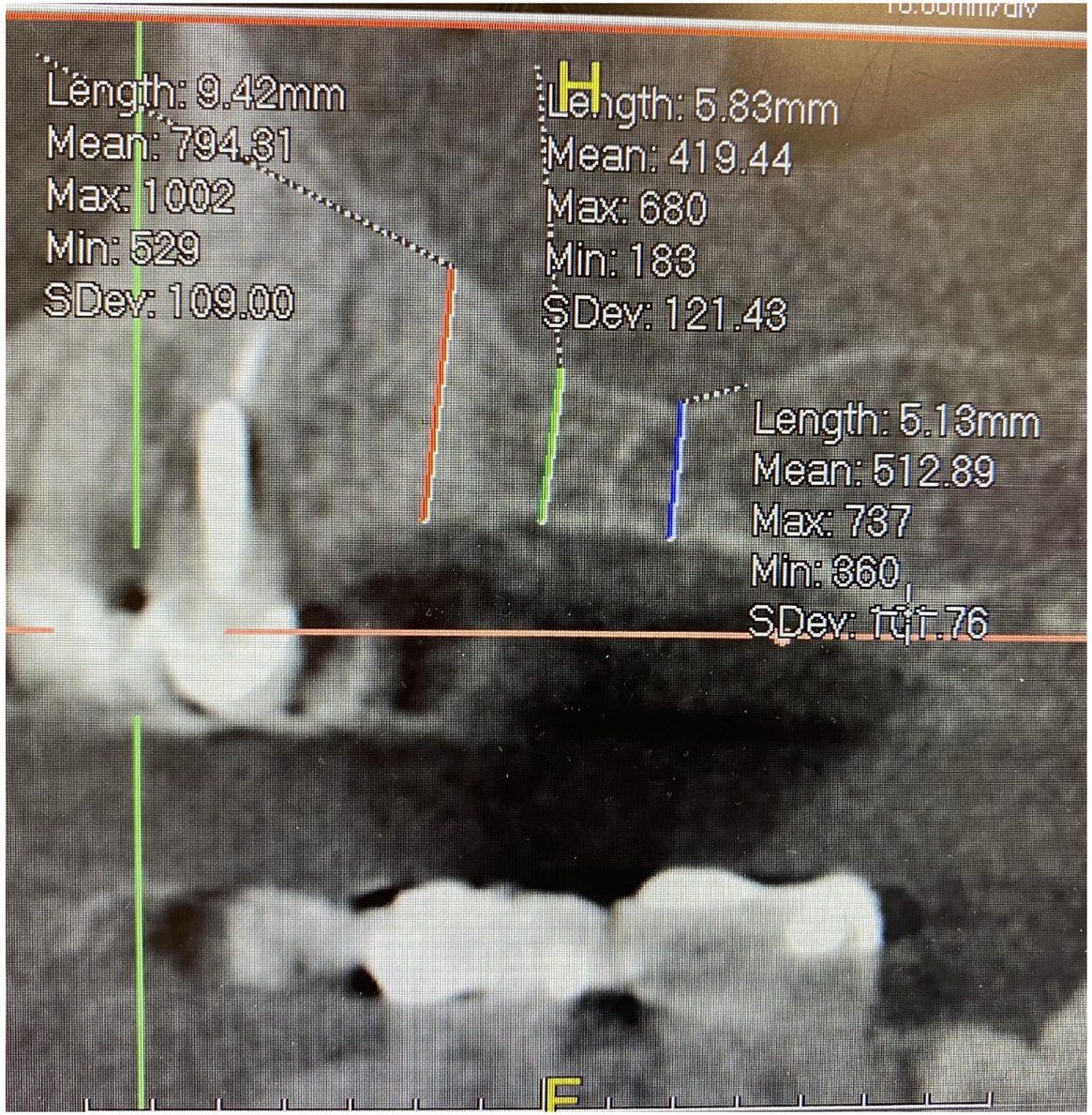

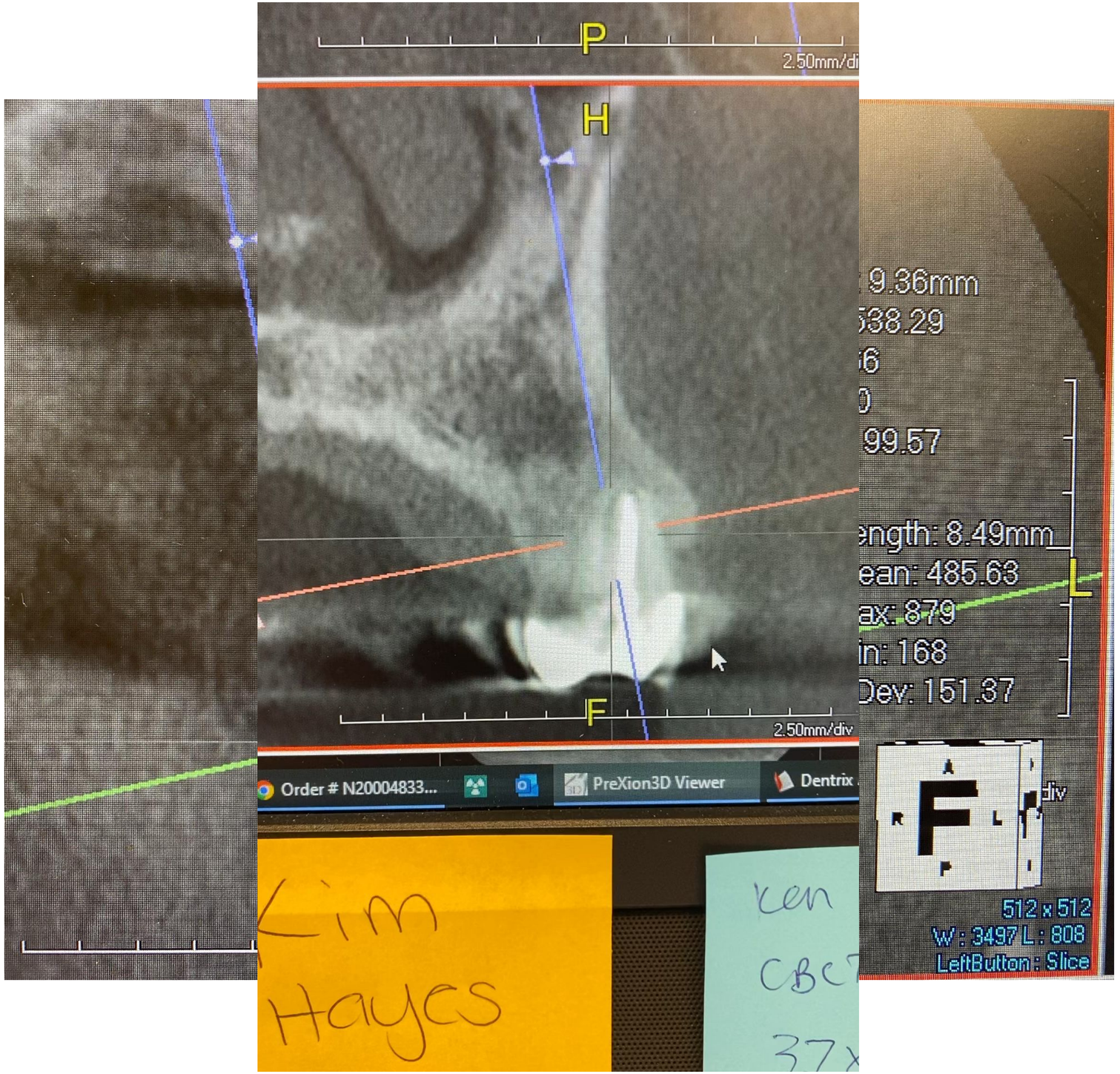
P
2.50mm/di
H
F
2.50mm/div
Order # N20004833...
PreXion3D Viewer
Dentrix
Kim
Hayes
ken
CBCT
37x
9.36mm
538.29
99.57
ength: 8.49mm
ean: 485.63
ax: 879
in: 168
Dev: 151.37
L
div
512 x 512
W: 3497 L: 808
LeftButton: Slice

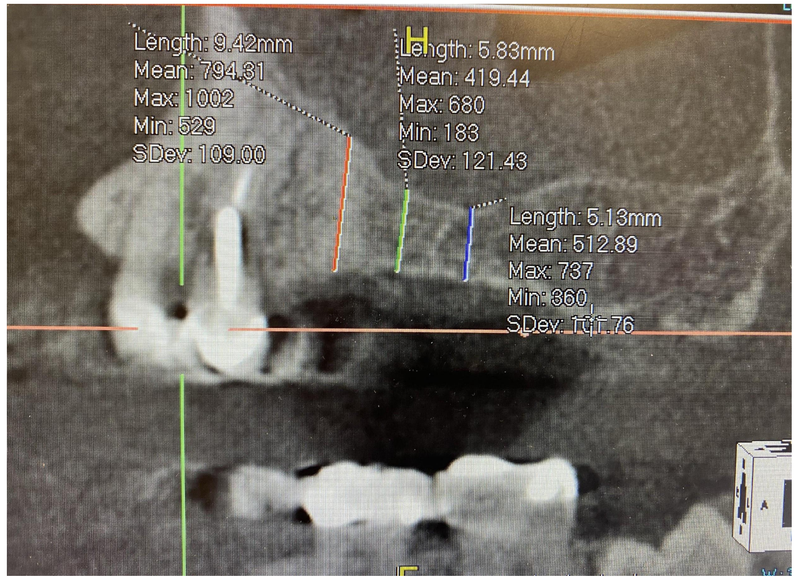
Length: 9.42mm
Mean: 794.31
Max: 1002
Min: 529
SDev: 109.00
H
Length: 5.83mm
Mean: 419.44
Max: 680
Min: 183
SDev: 121.43
Length: 5.13mm
Mean: 512.89
Max: 737
Min: 360
SDev: 101.76

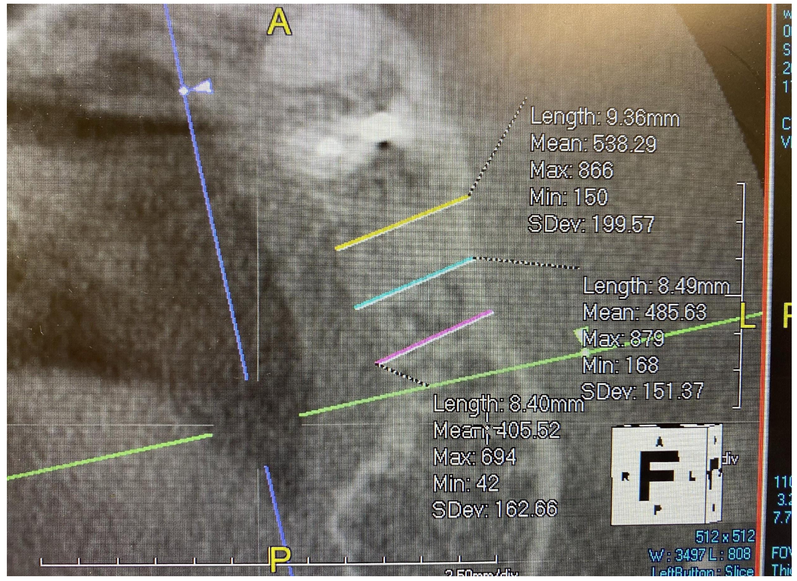
A
Length: 9.36mm
Mean: 538.29
Max: 866
Min: 150
SDev: 199.57
Length: 8.49mm
Mean: 485.63
Max: 879
Min: 168
SDev: 151.37
Length: 8.40mm
Mean: 405.52
Max: 694
Min: 42
SDev: 162.66
L
P
512 x 512
W: 3497 L: 808